

**PODOLIA AS A CULTURAL
CONTACT AREA
IN THE 4TH/3RD-2ND MILLENNIUM BC**

**Maciej Chyleński
Tomasz Goslar
Marta Gwizdała
Svetlana V. Ivanova
Mattias Jakobsson
Anna Juras
Viktor I. Klochko
Aleksander Koško
Liudmyla V. Litvinova
Sylvia Łukasik
Helena Malmström
Mykhailo V. Potupchyk
Serhiy M. Razumov
Marzena Szmyt
Gennadiy N. Toshev
Piotr Włodarczak
Danuta Żurkiewicz**

BALTIC-PONTIC STUDIES

V O L U M E 20 • 2015

BALTIC-PONTIC STUDIES

61-614 Poznań (Poland)

Umultowska 89D

Tel. 618291418

E-mail: antokol@amu.edu.pl

EDITOR

Aleksander Koško

EDITORIAL COMMITTEE

Sophia S. Berezanskaya (Kyiv), Lucyna Domańska (Łódź),
Elena G. Kalechyts (Minsk), Viktor I. Klochko (Kyiv), Mykola
N. Kryvaltsevich (Minsk), Roman Lytvynenko (Donieck), Jan
Machnik (Kraków), Przemysław Makarowicz (Poznań), Vitaliy
V. Otroshchenko (Kyiv), Marzena Szmyt (Poznań), Petro
Tolochko (Kyiv)

SECRETARY

Marzena Szmyt

SECRETARY OF VOLUME

Karolina Harat

Danuta Żurkiewicz

ADAM MICKIEWICZ UNIVERSITY
INSTITUTE OF EASTERN STUDIES
INSTITUTE OF PREHISTORY

Poznań 2015

ISBN 83-86094-20-6

ISSN 1231-0344

**PODOLIA AS A CULTURAL
CONTACT AREA
IN THE 4TH/3RD-2ND MILLENNIUM BC**

**Maciej Chyleński
Tomasz Goslar
Marta Gwizdała
Svetlana V. Ivanova
Mattias Jakobsson
Anna Juras
Viktor I. Klochko
Aleksander Koško
Liudmyla V. Litvinova
Sylvia Łukasik
Helena Malmström
Mykhailo V. Potupchyk
Serhiy M. Razumov
Marzena Szmyt
Gennadiy N. Toshev
Piotr Włodarczak
Danuta Żurkiewicz**

BALTIC-PONTIC STUDIES

V O L U M E 20 • 2015

© Copyright by BPS and Authors
All rights reserved

Reviewers: Lucyna Domańska
Przemysław Makarowicz

Cover Design: Eugeniusz Skorwider

Linguistic consultation: Ryszard J. Reisner
Piotr T. Żebrowski

Printed in Poland

Computer typeset by PSO Sp. z o.o. w Poznaniu

Printing: Zakłady Poligraficzne TMDRUK in Poznań

CONTENTS

EDITOR'S FOREWORD	5
EDITORIAL COMMENT.....	6
Svetlana V. Ivanova, Gennadiy N. Toshev, LATE ENEOLITHIC AND BRONZE AGE PROLOGUE PONTIC SOCIETIES. FOREST-STEPPE MIDDLE DNIESTER AND PRUT DRAINAGE BASINS IN THE 4TH/3RD-2ND MILLENNIUM BC: A HISTORY OF INVESTIGATIONS	7
Viktor I. Klochko, Aleksander Koško, Serhiy M. Razumov, Piotr Włodarczak, Danuta Żurkiewicz, ENEOLITHIC, YAMNAYA, CATACOMB AND BABYNO CULTURE CEMETERIES, PIDLISIVKA, BARROW 1, YAMPIL REGION, VINNITSA OBLAST: ARCHAEOOMETRY, CHRONOMETRY AND TAXONOMY	40
Viktor I. Klochko, Aleksander Koško, Serhiy M. Razumov, Piotr Włodarczak, Danuta Żurkiewicz, ENEOLITHIC, YAMNAYA AND NOUA CULTURE CEMETERIES FROM THE FIRST HALF OF THE 3RD AND THE MIDDLE OF THE 2ND MILLENNIUM BC, POROHY, SITE 3A, YAMPIL REGION, VINNITSA OBLAST: ARCHAEOOMETRIC AND CHRONOMETRIC DESCRIPTION, RITUAL AND TAXONOMIC-TOPOGENETIC IDENTIFICATION	78
Viktor I. Klochko, Aleksander Koško, Serhiy M. Razumov, Piotr Włodarczak, Danuta Żurkiewicz, ENEOLITHIC, BABYNO AND NOUA CULTURE CEMETERIES, KLEMBIVKA, SITE 1, YAMPIL REGION, VINNITSA OBLAST: ARCHAEOOMETRY, TAXONOMY AND TOPOGENETICS.....	142
Viktor I. Klochko, Aleksander Koško, Mykhailo V. Potupchuk, Piotr Włodarczak, Danuta Żurkiewicz, Svetlana V. Ivanova, TRIPOLYE (GORDINEȘTI GROUP), YAMNAYA AND CATACOMB CULTURE CEMETERIES, PRYDNISTRYANSKE, SITE 1, YAMPIL REGION, VINNITSA OBLAST: AN ARCHAEOOMETRIC AND CHRONOMETRIC DESCRIPTION AND A TAXONOMIC AND TOPOGENETIC DISCUSSION	183
Tomasz Goslar, Viktor I. Klochko, Aleksander Koško, Piotr Włodarczak, Danuta Żurkiewicz, CHRONOMETRY OF LATE ENEOLITHIC AND 'EARLY BRONZE' CULTURES IN THE MIDDLE DNIESTER AREA: INVESTIGATIONS OF THE YAMPIL BARROW COMPLEX.....	256
Liudmyla V. Litvinova, Sylwia Łukasik, Danuta Żurkiewicz, Marta Gwizdała, Maciej Chyleński, Helena Malmström, Mattias Jakobsson, Anna Juras, ANTHROPOLOGICAL DESCRIPTION OF SKELETAL MATERIAL FROM THE DNIESTER BARROW-CEMETERY COMPLEX, YAMPIL REGION, VINNITSA OBLAST (UKRAINE)	292

Svetlana V. Ivanova, Gennadiy N. Toshev, THE MIDDLE-DNIESTER CULTURAL CONTACT AREA OF EARLY METAL AGE SOCIETIES. THE FRONTIER OF PONTIC AND BALTIC DRAINAGE BASINS IN THE 4TH/3RD-2ND MILLENNIUM BC..... 336

Svetlana V. Ivanova, Viktor I. Klochko, Aleksander Koško, Marzena Szmyt, Gennadiy N. Toshev, Piotr Włodarczak, ‘YAMPIL INSPIRATIONS’: A STUDY OF THE DNIESTER CULTURAL CONTACT AREA AT THE FRONTIER OF PONTIC AND BALTIC DRAINAGE BASINS 406

List of Authors 425

Editor's Foreword

The present volume of *Baltic-Pontic Studies* comprises papers reflecting a segment of research into the *Podolia cultural interchange* of communities genetically related to the drainage basins of the Black and Baltic seas in the 4th/3rd-2nd millennium BC. Accordingly, the papers present the results produced by the Polish-Ukrainian research project whose aim was to explore the *Yampil barrow cemetery complex* located in the southern portion of the Middle Dniester Area (*Vinnitsa Oblast*).*

The respective papers discuss the Yampil cultural background – a taxonomic record of ‘barrow communities’ settling the forest-steppe zone of the drainage basins of the Dniester and Prut rivers (from the position of the state the investigations of them have been until now). Next, they present the archaeometric and taxonomic descriptions of cemeteries explored by the *Yampil Expedition* in 2010-2015 (Klembivka, Pidlisivka, Porohy, Prydnistryanske) and further, examine the chronometry and anthropological characteristics of the populations that co-created the necropolises in question.

This volume of papers includes synthesizing studies that, while continuing to examine the questions raised earlier, focus on ‘Podolia conceptual propositions’ in the context of Baltic-Pontic archaeology. This particular research focus shall be continued in subsequent volumes of *BPS*.

The requirements related to *BPS* going electronic are the reason behind the limited modification of its editorial formula, which readers will see on the pages of this volume.

The present 20th volume has been made possible owing to the generous financial support provided for undertaking scholarly investigation and associated editing, and publishing, as well as administration under the aegis of a grant from the *National Programme for the Development of the Humanities* (no. 108/NPH3/H12/82/2014).

The reviewers of the papers published in this volume were Professors Lucyna Domańska and Przemysław Makarowicz.

* For a broader discussion see: ‘Naddniestrzańskie kompleksy cmentarzysk kurhanowych społeczności z III i z pierwszej połowy II tysiąclecia przed Chr. w okolicach Jampola, obwód winnicki. Z badań nad północno-zachodnią rubieżą osadnictwa kręgu kultur „wczesnobrązowych” strefy pontyjskiej. Badania z lat 1984-2014 In: Aleksander Koško, Mychajł Potupchyk, Serhiy Razumov (Eds) *Archaeologia Bimaris – Monografie* 6. Poznań: Wydawnictwo Nauka i Innowacje.

Editorial comment

1. All dates in the B-PS are calibrated [BC; see: Radiocarbon vol. 28, 1986, and the next volumes]. Deviations from this rule will be point out in notes [bc].
2. The names of the archaeological cultures and sites are standarized to the English literature on the subject (e.g. M. Gimbutas, J.P. Mallory). In the case of a new term, the author's original name has been retained.
3. The spelling of names of localities having the rank of administrative centres follows official, state, English language cartographic publications (e.g. *Ukraine, scale 1 : 2 000 000*, Kyiv: Mapa LTD, edition of 1996; *Rèspublika BELARUS', REVIEW-TOPOGRAPHIC MAP*, scale 1:1 000 000, Minsk: *BYELORUSSIAN CARTOGRAPHIC AN GEODETIC ENTERPISE*, edition 1993).

Liudmyla V. Litvinova*, **Sylvia Łukasik****, **Danuta Żurkiewicz*****,
Marta Gwizdała****, **Maciej Chyleński*******, **Helena Malmström*******,
Mattias Jakobsson*****, **Anna Juras*******

ANTHROPOLOGICAL DESCRIPTION OF SKELETAL
MATERIAL FROM THE DNIESTER BARROW-
CEMETERY COMPLEX, YAMPIL REGION,
VINNITSA OBLAST (UKRAINE)

ABSTRACT

Anthropological examinations were performed on skeletal material from four barrow necropolises located in the Yampil Region (Ukraine) and dated to the Eneolithic, Bronze Age and Iron Age. The purpose of the examinations was the determination of sex and age at death of individuals, reconstruction of their stature and assessment of their status of health. The examinations covered 61 individuals: 17 children

* Department of Bioarchaeology, Institute of Archaeology, Ukrainian Academy of Science, Geroiv Stalingrada ave. 12, 04210 Kyiv, Ukraine; litvinovalv@ukr.net

** Department of Human Evolutionary Biology, Institute of Anthropology, Faculty of Biology, Adam Mickiewicz University in Poznań, Umultowska 89, 61-614 Poznań, Poland; lukasik@amu.edu.pl

*** Department of Prehistory of Central and Eastern Europe, Institute of Prehistory, Faculty of History, Adam Mickiewicz University in Poznań; Umultowska 89D, 61-614 Poznań, Poland; danuta@amu.edu.pl

**** Institute of Prehistory, Faculty of History, Adam Mickiewicz University in Poznań, Umultowska 89D, 61-614 Poznań, Poland; marta-gwizdala@wp.pl

***** Department of History, Institute of Prehistory, Faculty of History, Adam Mickiewicz University in Poznań, Umultowska 89d, 61-614 Poznań, Poland; maciejchylenski@gmail.com

***** Department of Organismal Biology and SciLifeLab; Uppsala University, Norbyvägen 18C, SE-752 36 Uppsala, Sweden; helena.malmstrom@ebc.uu.se

***** Department of Organismal Biology and SciLifeLab, Uppsala University, Norbyvägen 18C, SE-752 36 Uppsala, Sweden; mattias.jakobsson@ebc.uu.se

***** Department of Human Evolutionary Biology, Institute of Anthropology, Faculty of Biology, Adam Mickiewicz University in Poznań, Umultowska 89, 61-614 Poznań, Poland; ajuras.anthropology@gmail.com

and 44 adults. Their health status was assessed using four common indicators: linear enamel hypoplasia, *cribra orbitalia*, porotic hyperostosis and dental caries.

Key words: Eneolithic, Yamnaya culture, Bronze Age, anthropology, Ukraine

In 2010-2014, a Polish-Ukrainian archaeological expedition investigated seven barrows situated on the middle Dniester, in the vicinity of the town of Yampil, Ukraine. The investigations formed part of a research project devoted to the exploration of Podolia as a cultural interchange in the 4th/3rd and 2nd millennia BC. An important aspect of the project was its interdisciplinary character which enhanced the cultural and biological picture of communities practising the barrow funerary rite.

The area of investigations probing a section of the Middle Dniester Area, administratively restricted to the Yampil Region (Vinnitsa *Oblast*), is characterized by a considerable concentration of barrow features. The area coincides with the north-western range of 'Early-Bronze' barrows, associated with eastern Europe's steppe and forest-steppe.

A detailed surface survey of the Yampil Region and earlier excavations carried out as part of conservation efforts helped reconstruct the cultural landscape of this space fragment. A recent summary of these efforts [Koško *et al.* 2014] shows that the building of most barrows in this area can be linked to Yamnaya culture (YC) communities, while the history of their later 'use' covers successive millennia: it involves later cultural units (Catacomb culture – CC; Babyno culture – BC and Noua culture – NC) as far as modern times. From the perspective of a single barrow, this presents a picture that is difficult to interpret for it encompasses an extensive funerary zone (cemetery), grouping successive burials, traces of ritual activities related to the cult of the dead and later funerary attempts to architecturally fashion the mound form.

About the biology of the builders and their successors of most tombs located in the area in question very little is known now. Relying on what is known about the YC eastern frontier in this context, specifically about the Middle Volga (over 1,500 km NE of Yampil), it can be concluded that the representatives of *Yampil communities* were taller and heavier than average. The results of investigations hitherto carried out show that about 40 per cent of individuals inhabiting the area under discussion in the Early Bronze Age had *cribra orbitalia*¹. Interestingly enough, for earlier and later communities the figure is only about 10 per cent. In addition, the 'Yamnaya' community on the Middle Volga was characterized by an almost absolute absence of caries [Anthony 2007: 326].

The high frequency of *cribra orbitalia* and low frequency of dental caries could have resulted, in the opinion of Anthony [2007], from the diet of mostly car-

¹ Resulting from iron deficiency, among other reasons.

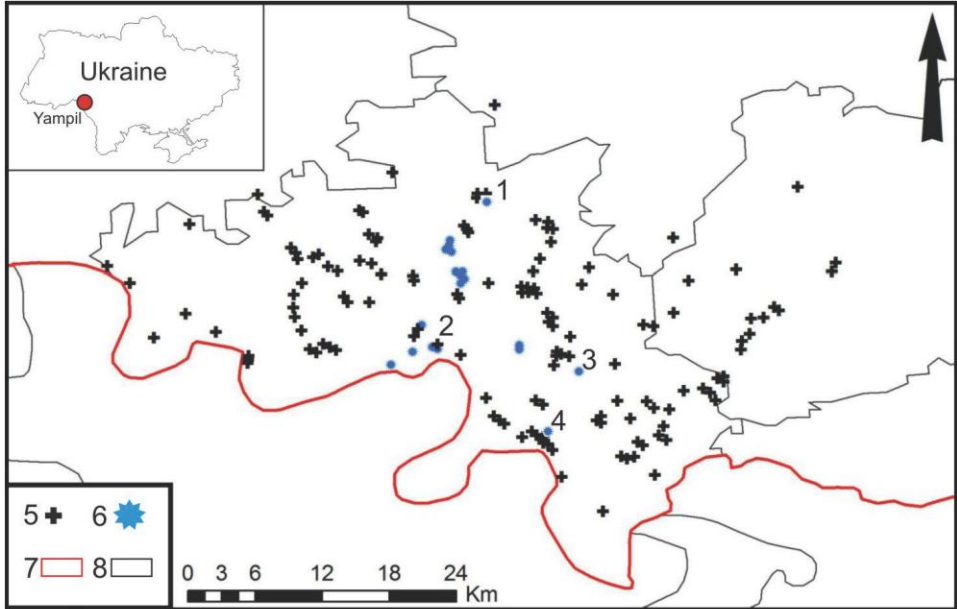


Fig. 1. Map of *Yampil* barrows, showing administrative borders: 1 – Klembivka barrow 1; 2 – Porohy, barrow 3A; 3 – Pidlisivka, barrow 1; 4 – Prydnistryanske, barrows 1-4; 5 – barrows; 6 – excavated barrows; 7 – Ukrainian-Moldovan frontier; 8 – Yampil Region border

bohydrate-poor (cereals) and protein-rich foods (blocking the assimilation of iron). The diet of past populations was strongly tied to their economic and settlement system. Mobile animal herding involving movement along large distances in wagons or on horseback supposedly resulted in the absence of any larger permanent settlements. Consequently, these populations' daily diet had only a small share of cereal products.

These observations correspond well to the widely adopted picture of YC communities, held to have consisted of patriarchal itinerant nomads-herders, living on a diet of mainly animal products, as well as mounted warriors defending their possessions.

Only slightly visible or totally obliterated today, mound forms were once a significant element of cultural landscapes, being loci around which everyday life centred. The study of central burials, around which the mound structure was formed and the other funeral space was built, indicates the dominant position of adult males to which barrows were dedicated. The patrilineal and patrilocal character of these communities follows also from the linguistic studies of Proto-Indo-European vocabulary [Anthony 2007: 304].

It is very hard to decide if a barrow was treated as a family cemetery and whether all the members of a given family were entitled to be buried in it. The

examination results of mtDNA fragments belonging to individuals from barrow 1, the Pidlisivka site (features 1A and 11), point to the possibility of relationship in the female line between two males buried in the central grave and in a feature placed underneath the mound later [Juras 2014]. However, to build a complete picture of the social structure and funerary rites of this community, more research is necessary.

The sites from which the studied material comes are located on the left bank of the Dniester. The barrows in Prydnistryanske (site 1, barrows I-IV) and Porohy (barrow 3A) lie on the edge of the river valley, while the barrows from Pidlisivka (barrow 1) and Klembivka (barrow 1) are located in the drainage basins of smaller watercourses emptying into the Dniester. The distances between particular sites are small, ranging from 7 to 22 km (Fig. 1). When the archaeological investigations began most mounds had already been largely levelled off. Their diameter ranged from about 25 to 49 m, while their height stayed between almost 1 m to about 4 m. By far, the greatest surviving height was that of barrow IV from Prydnistryanske. Features from this site, associated with the Eneolithic populations of the Gordinești group of the Tripolye culture (TC-G) and the Early Bronze YC make up the most developed chronological sequence of the ceremonial-funerary centre the beginnings of which are dated to the second half of the 4th millennium BC, while the decline of continuous use falls on the first half of the 3rd millennium BC. It grew in importance, however, yet again in the Iron Age. The chronology of the other sites also fits into the mentioned time interval [Goslar *et al.* 2015], adding to this sequence the burials of the Babyno and Noua communities from the 2nd millennium BC.

The skeletal material from the above-named sites were studied to determine sex and age at death as well as to reconstruct the stature of particular individuals and evaluate their status of health.

1. DESCRIPTION OF SOURCES

Analyses were performed altogether on 61 individuals: 13 from Pidlisivka 1, 11 from Klembivka 1, 20 from Porohy 3A and 17 from Prydnistryanske 1. There were far more adults than children (Tab. 1 and Supplement 1). The skeletal material was poorly preserved and incomplete for the most part, which greatly limited research possibilities. Out of all individuals, only 23 could be subjected to the examination of *cribra orbitalia* (36.5%), 11 to porotic hyperostosis (17.5%), 21 to linear enamel hypoplasia (33.3%) and 30 to dental caries (47.6%) (*see* Supplement 2).

Number of individuals studied

Site	Children		Adults		Total	
	N	%	N	%	N	%
Pidlisivka 1	6	35.3	7	15.9	13	21.3
Klembivka 1	3	17.6	8	18.2	11	18.0
Porohy 3A	5	29.4	15	34.1	20	32.8
Prydnistryanske 1	3	17.6	14	31.8	17	27.9
Total	17	27.9	44	72.1	61	100

2. ANTHROPOLOGICAL METHODS

Age at death and sex of individuals were determined using standard anthropological methods [Baker *et al.* 2005; Buikstra, Ubelaker 1994; Schaefer *et al.* 2009; White, Folkens 2005]. The age of subadults was determined by evaluating the tooth development and eruption, skeleton ossification as well as bone measurements. The age of adults, in turn, was determined on the basis of the degree of obliteration of cranial sutures, the tooth wear and changes on the surface of the pubic symphysis. It was necessary to use various methods of age determination because the skeletal material was rather poorly preserved and incomplete. The sex of adult individuals was determined, referring to the morphological characteristics of the skull and pelvis. Additionally, a molecular determination of sex assignment was performed for some of the individuals, in particular for infants and juveniles as well as for those specimens where anthropological sex determination was uncertain (*see* ancient DNA analysis).

For the purpose of evaluating the state of health, the following indicators were used: linear enamel hypoplasia (LEH), *cribra orbitalia* (CO), porotic hyperostosis (PH) and dental caries. Hypoplastic defects were assessed on incisors, canines, and premolars according to the recommendations of Goodman and Rose [1990]. To assess the age of particular lines, the method of Goodman and Rose [1990] was used. The degree of intensity of *cribra orbitalia* was assessed by applying the active/healing scale together with the scale of the Global History of Health Project (GHHP) [Steckel *et al.* 2005]. The degree of intensity of PH was also assessed by applying the GHHP scale [Steckel *et al.* 2005]. Caries was assessed on all tooth categories, both deciduous and permanent. Teeth were examined macroscopically without using any magnifying instruments.

Furthermore, data on injuries, degenerative lesions and inflammations, were collected together with information on other pathologies of the masticatory organ (dental calculus and abscesses). With respect to adult individuals, their stature was reconstructed, using the method developed by Trotter and Gleser [1952].

2.1. ANCIENT DNA ANALYSIS

Samples. In order to obtain molecular determination of sex, we performed ancient DNA (aDNA) analysis of 10 specimens from archaeological sites in Pidlisivka 1 (2 individuals), Poroxy 3A (2 individuals), Klembivka 1 (2 individuals) and Prydnistryanske 1 (4 individuals). Two intact teeth from each individual were collected using gloves and face masks to minimize the possibility of contaminations from modern humans. Molecular studies were conducted in the laboratory, at the Adam Mickiewicz University in Poznań, which is dedicated exclusively to the analysis of ancient DNA. All the precautions against modern DNA contaminations were taken as described earlier [Juras *et al.* 2014].

DNA extraction and library preparation. Prior to the extraction of a DNA, each tooth was cleaned with the use of ~5% NaOCl, followed by UV irradiation and drilling with Dremel® drill bits. DNA was extracted using the silica-based method according to Yang *et al.* [1998], modified by adding urea as in Svensson *et al.* [2008]. Twenty microliters of DNA were used to build blunt-end libraries [Mayer and Kircher 2010], skipping the initial nebulization step. Amplification and purification was conducted as in [Günther *et al.* 2015] with minor modifications. Concentrations and length distribution of DNA fragments were estimated using High Sensitivity D1000 Screen Tape assay on 2200 Tape Station system (Agilent). DNA libraries were shotgun sequenced on Illumina's HiSeq2500 (1250bp, pair end) or on Hi Seq X Ten (150bp, paired-end) at the SNP & SEQ technology platform Sci Life Sequencing Centre in Uppsala, Sweden. Obtained paired-end reads were demultiplexed, merged, and trimmed. The merged and trimmed reads were subsequently mapped to the human reference genome using BWA [Li, Durbin 2009]. The reads were then filtered for duplicates using Python scripts provided by Kircher [2012], and all reads with a minimum length of 35 base pairs were analyzed using same tools [Li *et al.* 2009].

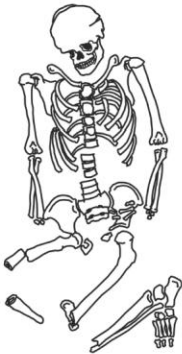
Molecular sexing. Molecular sex was determined using the method of Skoglund *et al.* [2013] based on the analysis of the ratio of sequence reads mapping to Y and X chromosomes (R_y) and restricted only to reads with mapping qualities of at least 30.

3.1. PIDLISIVKA 1

From the Pidlisivka 1 site, skeletal material belonging to 13 individuals were recovered: seven adults and six children (Tab. 2) [Bednarek *et al.* 2014; Klochko *et al.* 2015a].

3.1.1. ENEOLITHIC BURIALS

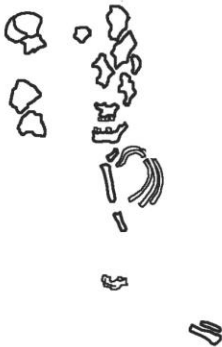Barrow 1, feature 1b



A poorly-preserved skeleton with a damaged skull. The preserved bones include large skull fragments, including facial bones, large fragments of lower and upper limb bones, small fragments of the pelvis, the sternum, scapula, foot bones, vertebrae and ribs. The skeleton belonged to a male aged 22-25 years (*adultus*).The molecular analysis corroborated the morphological sex assessment. Due to the poor state of preservation of long bones, it was not possible to reconstruct his stature.

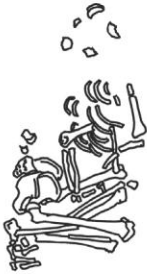Palaeopathological lesions: LEH on the upper left medial incisor (age of the individual at the time of defect: 2.5-3.0 years); a deformation of the left mastoid process.

Barrow 1, feature 10

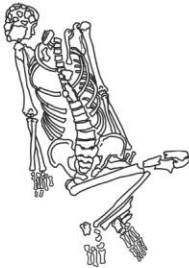

A poorly-preserved skeleton with a badly damaged skull. The preserved bones include small fragments of the cranial vault, maxillae and the mandible, as well as vertebrae and ribs. The skeleton belonged to a child aged 0-9 months (*infans I*). No palaeopathological lesions were observed.

3.1.2. YAMNAYA CULTURE BURIALS

Barrow 1, feature 1a

Skeleton 1. A poorly-preserved skeleton with a badly damaged skull. Three small fragments of cranial vault bones and lower and upper limb bones have been preserved. The skeleton belonged to a child aged 7-8 years (*infans II*). No palaeopathological lesions were observed.

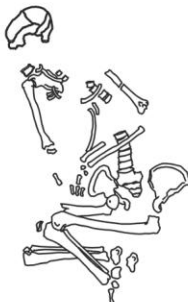


Skeleton 2. A poorly-preserved skeleton with a badly damaged skull. Small fragments of cranial bones (cranial vault and mandible) were recovered together with the bones of upper and lower limbs and fragments of the pelvis. The skeleton belonged to a male aged 30-40 years (*adultus/maturus*). Due to the poor state of preservation of long bones, it was not possible to reconstruct his stature.

Palaeopathological lesions: dental calculus, degenerative lesions at proximal and distal ends of tibiae and femora.

Barrow 1, feature 9

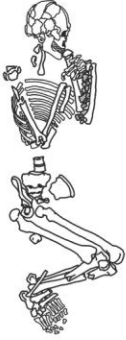
A poorly-preserved skeleton with a badly damaged skull. The preserved skeletal material include small fragments of skull and long bones (ulna and tibia) and a fragment of a scapula. The skeleton belonged to a child aged 0-1 years (*infans I*). No palaeopathological lesions were observed.

Barrow 1, feature 11

A poorly-preserved skeleton with a badly damaged skull. The preserved bones include small fragments of the cranial vault and the mandible, as well as small fragments of upper and lower limb bones and the pelvis. The skeleton belonged to a male aged 35-40 years (*maturus*). Due to the poor state of preservation of long bones, it was not possible to reconstruct his stature.

Palaeopathological lesions: dental calculus; considerable lowering of alveolar processes

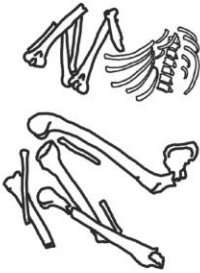
Barrow 1, feature 5



A poorly-preserved skeleton with a badly damaged skull. The preserved bones include small fragments of the skull (bones of the cranial vault and the facial skeleton), large fragments of long bones, small fragments of the pelvis, ribs and foot bones. The skeleton belonged to a male aged 30-35 years (*adultus*). Due to the poor state of preservation of long bones, it was not possible to reconstruct his stature.

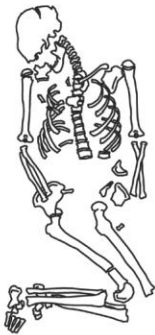
Palaeopathological lesions: LEH on both upper incisors, the right upper first premolar and right lower canine (age of the individual at the time of respective defects: 3.5-4.0, 2.5-3.0, 2.5-3.0years).

Barrow 1, feature 13



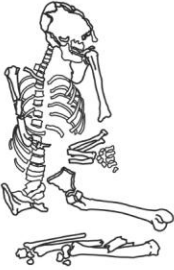A poorly-preserved skeleton with a badly damaged skull. The preserved bones include small fragments of the skull (bones of the cranial vault and maxillae), large fragments of upper and lower limb bones (epiphyses are damaged). The skeleton most probably belonged to a female aged 20-25 years (*adultus*). The molecular analysis corroborated the morphological sex assessment. Due to the poor state of preservation of long bones, it was not possible to reconstruct her stature. No palaeopathological lesions were observed.

Barrow 1, feature 4



A poorly-preserved skeleton with a badly damaged skull. The preserved bones include small fragments of the cranial vault, fragments of upper limb bones, small fragments of the pelvis, ribs, vertebrae and foot bones. The skeleton belonged to a child aged 11-12 years (*infans II*).

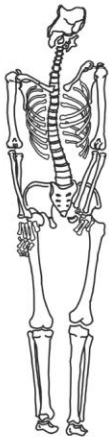Palaeopathological lesions: LEH on the upper left canine and lower right first premolar (age of the individual at the time of both defects: 4.5-5.0 years).

Barrow 1, feature 7

A poorly-preserved skeleton with a badly damaged skull. The preserved bones include small fragments of the cranial vault, a small fragment of the mandible, as well as small fragments of upper and lower limb bones. The skeleton could have belonged to a male aged 25-30 years (*adultus*). Due to the poor state of preservation of long bones, it was not possible to reconstruct his stature.

Palaeopathological lesions: dental calculus; LEH on all upper premolars and lower first premolars (age of the individual at the time of respective defects: 5.0-5.5, 4.5-5.0, 4.5-5.0, 4.5-5.0, 4.0-4.5, 3.5-4.0 years); injury sustained during the individual's lifetime recorded on a small fragment of the nasal bone (no traces of inflammation were recorded).

3.1.5. IRON AGE BURIAL

Barrow 1, feature 12

A well-preserved skeleton with a badly damaged skull. The preserved bones include small fragments of the cranial vault (occipital bone and left parietal bone), a small fragment of the mandible, as well as large fragments of upper and lower limb bones, pelvis, foot bones, phalanges, vertebrae and ribs. The skeleton belonged to a male aged 50-55 years (*maturus*). Due to the poor state of preservation of long bones, it was not possible to reconstruct his stature.

Palaeopathological lesions: the upper left second molar showed signs of caries; thoracic vertebrae had Schmorl's nodes, while lumbar vertebrae carried Schmorl's nodes and osteophytes; dental calculus and a considerable lowering of alveolar processes could be observed. The upper left third molar was lost *antemortem*. On the left maxilla, over the upper second molar, dental abscesses were recorded. Degenerative lesions of the left acetabulum of the hip joint, proximal end of a hand phalanx and ribs were observed.

3.1.6. BURIALS OF AN INDETERMINATE CHRONOLOGY

Barrow 1, mound

A poorly-preserved skeleton with a badly damaged skull. The preserved bones include a fragment of the right temporal bone and maxilla, small fragments of the

scapula and pelvis, large fragments of upper and lower limb bones (epiphyses are not fused). The skeleton belonged to an individual aged 15-20 years (*juvenis*).

Palaeopathological lesions: dental calculus.

Barrow 1, feature 8

A poorly-preserved skeleton: a fragment of the right femur, a small fragment of the ulna and fine fragments of ribs were recorded. The skeleton belonged to a child aged 1-6 years (*infans I*). No palaeopathological lesions were observed.



Table 2

Basic information on skeletal material from barrow 1, Pidlisivka site

Site	Grave	Anthropological Age Determination	Anthropological Sex Assignment	Molecular Sex Assignment	Archaeological Culture
Pidlisivka	Mound	<i>Juvenis</i> (15-20 years)	---	Not done	?
Pidlisivka	Feature 1a Skeleton 1	<i>Infans II</i> (7-8 years)	---	Not done	YC
Pidlisivka	Feature 1a Skeleton 2	<i>Adultus/maturus</i> (30-40 years)	Male	Not done	YC
Pidlisivka	Feature 1b	<i>Adultus</i> (22-25 years)	Male	XY	Eneolithic
Pidlisivka	Feature 4	<i>Infans II</i> (11-12 years)	---	Not done	CC
Pidlisivka	Feature 5	<i>Adultus</i> (30-35 years)	Male	Not done	BC
Pidlisivka	Feature 7	<i>Adultus</i> (25-30 years)	Male?	Not done	CC
Pidlisivka	Feature 8	<i>Infans I</i> (1-6 years)	---	Not done	?
Pidlisivka	Feature 9	<i>Infans I</i> (0-1 year)	---	Not done	YC
Pidlisivka	Feature 10	<i>Infans I</i> (0-9 months)	---	Not done	Eneolithic
Pidlisivka	Feature 11	<i>Maturus</i> (35-40 years)	Male	Not done	YC
Pidlisivka	Feature 12	<i>Maturus</i> (50-55 years)	Male	Not done	Iron Age
Pidlisivka	Feature 13	<i>Adultus</i> (20-25 years)	Female?	XX	BC

3.2. POROHY 3A

From the Porohy site, skeletal material belonging to 20 individuals were recovered: 15 adults and 5 children (Tab. 3) [Klochko *et al.* 2015b].

3.2.1. ENEOLITHIC BURIALS

Barrow 3A, feature 14

Individual 1. Bones found in the feature fill were very poorly preserved. They included a few fragments of the cranial vault. The skeleton belonged to a child. Due to the poor state of bone preservation, it was not possible to determine the exact age of the individual. No palaeopathological lesions were observed.

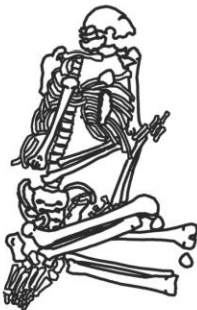Barrow 3A, feature 14

Individual 2. Bones found in the feature fill were very poorly preserved. They included a few fragments of the skull, a fragment of the ulna and another of the fibula, and a fragment of the sacrum, as well as foot phalanges. The skeleton belonged to an adult. Due to the poor state of bone preservation, it was not possible to reconstruct the individual's stature nor estimate his or her age-at-death nor determine sex. No palaeopathological lesions were observed.

Barrow 3A, feature 18

A very poorly-preserved skeleton: only small fragments of long bones were recovered. The skeleton most probably belonged to a child aged 0-7 years (*infans I*). No palaeopathological lesions were observed.

3.2.2. YAMNAYA CULTURE BURIALS

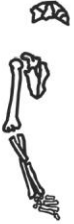Barrow 3A, feature 1

A poorly-preserved skeleton with a badly damaged skull. The preserved bones include very small fragments of the skull, upper and lower limbs, pelvis and foot. The skeleton belonged to a male aged 30-35 years (*adultus*). Due to the poor state of preservation of long bones, it was not possible to reconstruct his stature.

Palaeopathological lesions: dental calculus and lowering of alveolar processes. The frontal bone bears traces of a compression fracture (located in the middle of the bone) and three

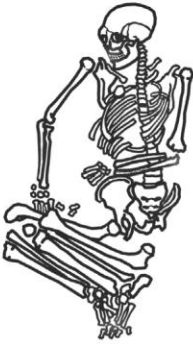
perforations (one located on the right side, two on the left), showing no traces of obliteration (healing). These can be traces of a ritual skull 'division'. Traces of artificial bone working can be also seen on the fragments of the parietal bones, occipital bone and the mandible; degenerative lesions were observed on vertebrae and phalanges.

Barrow 3A, feature 2



A very poorly-preserved skeleton with a badly damaged skull. The preserved bones include small fragments of the cranial vault, humerus, radius and ulna. The skeleton most probably belonged to a male aged 35-55 years (*maturus*). Due to the poor state of preservation of long bones, it was not possible to reconstruct his stature. No palaeopathological lesions were observed.

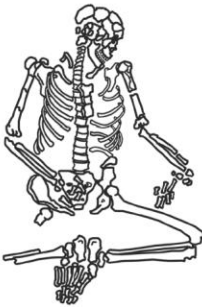
Barrow 3A, feature 10



A very poorly-preserved skeleton with a badly damaged skull. The preserved bones include small fragments of the cranial vault and mandible and larger ones of the upper and lower limbs, pelvis fragments and vertebrae. The skeleton belonged to a female aged 25-30 years (*adultus*). Due to the poor state of preservation of long bones, it was not possible to reconstruct her stature.

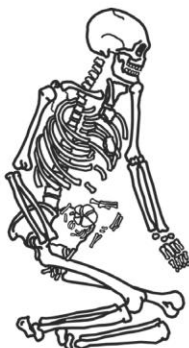
Palaeopathological lesions: LEH on both lower canines (age of the individual at the time of both defects: 4.5-5.0 years); caries on the upper left third molar.

Barrow 3A, feature 11



A poorly-preserved skeleton with a badly damaged skull. The preserved bones include small fragments of the skull, upper and lower limbs, small fragments of the pelvis. The skeleton belonged to a male aged 25-30 years (*adultus*). Due to the poor state of preservation of long bones, it was not possible to reconstruct his stature.

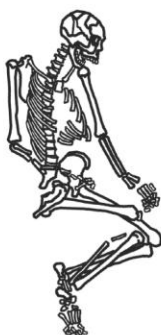Palaeopathological lesions: dental calculus; amidst pelvis fragments, a flint arrow point was found, but due to the poor state of bone preservation, it is not possible to determine its original location.

Barrow 3A, feature 12

Skeleton 1. A poorly-preserved skeleton with a badly damaged skull. The preserved bones include fragments of the cranial vault, large fragments of upper limb bones (epiphyses are damaged), small fragments of the pelvis, and foot bones. The skeleton belonged to a female aged 22-25 years (*adultus*). The molecular analysis corroborated the morphological sex assessment. The stature of the individual was approx. 160 cm.

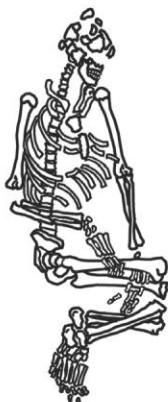Palaeopathological lesions: porotic hyperostosis (1st degree according to GHHP) of the right parietal bone; dental calculus.

Skeleton 2. A well-preserved skeleton with a badly damaged skull. The preserved bones include small fragments of the skull, upper and lower limbs, pelvis, vertebrae and ribs. The skeleton belonged to a child (foetus). No palaeopathological lesions were observed.

Barrow 3A, feature 15

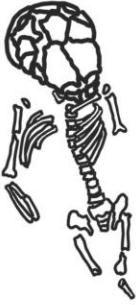A poorly-preserved skeleton with a badly damaged skull. The preserved bones include small fragments of the skull, upper and lower limbs, and vertebrae. The skeleton belonged to a male aged 25-30 years (*adultus*). Due to the poor state of preservation of long bones, it was not possible to reconstruct his stature.

Palaeopathological lesions: degenerative lesions on the proximal ends of metatarsal bones and two phalanges.

Barrow 3A, feature 17

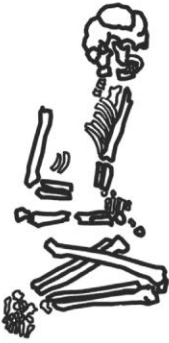A poorly-preserved skeleton with a badly damaged skull. The preserved bones include small fragments of the skull, upper and lower limb bones (epiphyses are partly damaged) and small fragments of the pelvis and vertebrae. The skeleton belonged to a male aged 30-35 years (*adultus*). Due to the poor state of preservation of long bones, it was not possible to reconstruct his stature.

Palaeopathological lesions: osteophytes on the olecranon of the right ulna; degenerative lesions on cervical vertebrae.

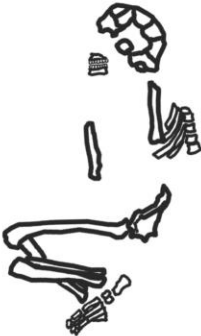Barrow 3A, feature 19

A poorly-preserved skeleton with a badly damaged skull. The preserved bones include very small fragments of the skull, upper and lower limb bones, pelvis and vertebrae. The skeleton belonged to a child aged 0-18 months (*infans I*).

Palaeopathological lesions: caries of the upper right second deciduous molar; *cribra orbitalia* (1st degree according to GHHP, type: healed) on the right orbital roof.

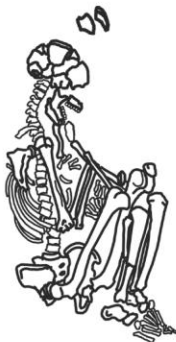Barrow 3A, feature 20

Skeleton 1. A very poorly-preserved skeleton with a badly damaged skull. The preserved bones include small fragments of the skull and lower limbs. The skeleton belonged to a male aged 50-55 years (*maturus*). Due to the poor state of preservation of long bones, it was not possible to reconstruct stature. No palaeopathological lesions were observed.



Skeleton 2. A very poorly-preserved skeleton with a badly damaged skull. The preserved bones include small fragments of the skull and lower limbs. The skeleton belonged to an adult aged 20-55 years (*adultus/maturus*). Due to the poor state of bone preservation, it was not possible to reconstruct the individual's stature. The results of molecular analysis implied this individual to be female. No palaeopathological lesions were observed.

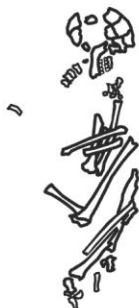3.2.3. NOUA CULTURE BURIALS

Barrow 3A, feature 5

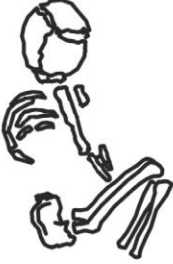A very poorly-preserved skeleton with a badly damaged skull. The preserved bones include small fragments of the skull, upper and lower limbs, pelvis fragments, vertebrae and foot bones. The skeleton belonged to a male aged 25-30 years (*adultus*). The stature of the individual was approx. 178 cm. No palaeopathological lesions were observed.

Barrow 3, feature 8

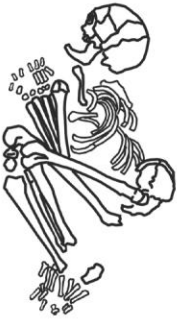A poorly-preserved skeleton with a badly damaged skull. The preserved bones include small fragments of the skull and lower and upper limbs, as well as small fragments of the pelvis. The skeleton belonged to a male aged 20-55 years (*adultus/maturus*). Due to the poor state of preservation of long bones, it was not possible to reconstruct his stature. No palaeopathological lesions were observed.

Barrow 3A, feature 22

A poorly-preserved skeleton with a badly damaged skull. The preserved bones include small fragments of the cranial vault, mandible fragments, small fragments of upper and lower limb bones. The skeleton belonged to a male aged 30-35 years (*adultus*). Due to the poor state of preservation of long bones, it was not possible to reconstruct his stature. No palaeopathological lesions were observed.

Barrow 3A, feature 3

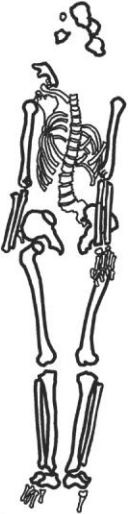A very poorly-preserved skeleton with a badly damaged skull. The preserved bones include small fragments of the skull and of long bones. The skeleton belonged to a child aged 0-3 years (*infans I*). No palaeopathological lesions were observed.

Barrow 3A, feature 7

A very poorly-preserved skeleton with a badly damaged skull. The preserved bones include small fragments of the cranial vault, pelvis and fragments of long bones. The skeleton most probably belonged to a male aged 35-55 years (*maturus*). Due to the poor state of preservation of long bones, it was not possible to reconstruct his stature.

Palaeopathological lesions: degenerative lesions were observed on vertebrae and phalanges.

3.2.4. IRON AGE BURIAL

Barrow 3A, feature 21

A poorly-preserved skeleton with a badly damaged skull. The preserved bones include small fragments of the skull and lower and upper limbs, as well as small fragments of the pelvis and vertebrae. The skeleton belonged to a female aged 45-50 years (*maturus*). Due to the poor state of preservation of long bones, it was not possible to reconstruct her stature.

Palaeopathological lesions: degenerative lesions on vertebrae.

Table 3

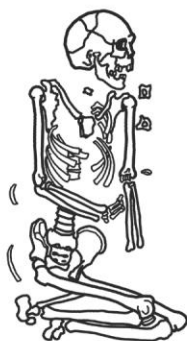
Basic information on skeletal material from Barrow 3A, Porohy site

Site	Grave	Anthropological Age Determination	Anthropological Sex Assignment	Molecular Sex Assignment	Archaeological Culture
Porohy 3A	Feature 1	<i>Adultus</i> (30-35 years)	Male	Not done	YC
Porohy 3A	Feature 2	<i>Maturus</i> (35-55 years)	Male?	Not done	YC
Porohy 3A	Feature 3	<i>Infans I</i> (0-3 years)	---	Not done	NC
Porohy 3A	Feature 5	<i>Adultus</i> (25-30 years)	Male	Not done	NC
Porohy 3A	Feature 7	<i>Maturus</i> (35-55 years)	Male?	Not done	NC
Porohy 3A	Feature 8	<i>Adultus/maturus</i> (20-55 years)	Male	Not done	NC
Porohy 3A	Feature 10	<i>Adultus</i> (25-30 years)	Female	Not done	YC
Porohy 3A	Feature 11	<i>Adultus</i> (25-30 years)	Male	Not done	YC
Porohy 3A	Feature 12 skeleton 1	<i>Adultus</i> (22-25 years)	Female	XX	YC
Porohy 3A	Feature 12 skeleton 2	Child (Foetus)	---	Not done	YC
Porohy 3A	Feature 14	Child (below 20 years)	---	Not done	Eneolithic
Porohy 3A	Feature 14	Adult (above 20 years)	?	Not done	Eneolithic
Porohy 3A	Feature 15	<i>Adultus</i> (25-30)	Male	Not done	YC
Porohy 3A	Feature 17	<i>Adultus</i> (30-35)	Male	Not done	YC
Porohy 3A	Feature 18	<i>Infans I</i> (0-7 years)	---	Not done	Eneolithic
Porohy 3A	Feature 19	<i>Infans I</i> (0-18 months)	---	Not done	YC
Porohy 3A	Feature 20 skeleton 1	<i>Maturus</i> (50-55 years)	Male	Not done	YC
Porohy 3A	Feature 20 skeleton 2	<i>Adultus/maturus</i> (20-55 years)	?	XX	YC
Porohy 3A	Feature 21	<i>Maturus</i> (45-50 years)	Female	Not done	Iron Age
Porohy 3A	Feature 22	<i>Adultus</i> (30-35 years)	Male	Not done	NC

From the Klembivka 1 site, skeletal material belonging to 11 individuals were recovered:² eight adults and three children (Tab. 4) [Klochko *et al.* 2015c].

3.3.1. ENEOLITHIC BURIALS

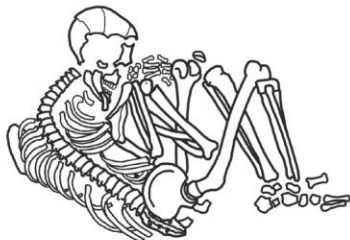
Barrow 1, feature 5



A poorly-preserved skeleton with a badly damaged skull. The preserved bones include small fragments of the skull and large fragments of upper and lower limb bones. The skeleton belonged to a male aged 50-55 years (*maturus*). Due to the poor state of preservation of long bones, it was not possible to reconstruct his stature.

Palaeopathological lesions: caries of both upper first molars, second upper left premolar, upper right second molar, both lower first molars, second left lower molar, both lower third molars; both lower first molars were lost *antemortem*; bilateral maxillary sinusitis; extreme lowering of alveolar processes; ossified ligaments on the right patella (enthesopathy); osteophytes on lumbar vertebrae; degenerative lesions on the right acetabulum of the hip joint and the odontoid process.

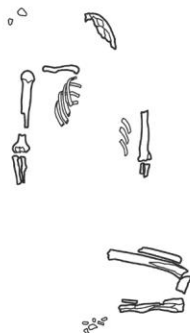
Barrow 1, feature 14



A poorly-preserved skeleton with a badly damaged skull. The preserved bones include small fragments of the skull, fragments of upper and lower limb bones, small fragments of the pelvis. The skeleton belonged to a male aged 25-30 years (*adultus*). Due to the poor state of preservation of long bones, it was not possible to reconstruct his stature.

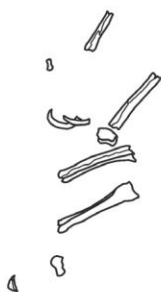Palaeopathological lesions: caries of the upper right first molar, upper left third molar, both lower second molars, both lower molars, lower right molar; porotic hyperostosis (1st degree according to GHHP) of the right parietal bone; dental calculus and lowering of alveolar processes; degenerative lesions of the proximal end of a hand phalanx.

² The anthropological report, due to the destruction of materials, ignored the remains of presumably, a child discovered on the Klembivka site within feature 6.

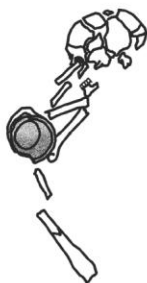
Barrow 1, feature 15

A poorly-preserved skeleton with a badly damaged skull. The preserved bones include small fragments of the cranial vault and fragments of upper and lower limb bones. The skeleton belonged to child aged 15-20 years (*juvenis*). No palaeopathological lesions were observed.

3.3.2. BABYNO CULTURE BURIALS

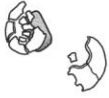Barrow 1, feature 2

A poorly-preserved skeleton. The preserved bones include small fragments of lower limb bones. The skeleton belonged to an adult individual. Due to the poor state of bone preservation, it was not possible to reconstruct the individual's stature nor estimate his or her age-at-death nor determine sex. No palaeopathological lesions were observed.

Barrow 1, feature 3

A poorly-preserved skeleton with a badly damaged skull. The preserved bones include fragments of the skull and lower limbs. The skeleton most probably belonged to a male aged 35-45 years (*maturus*). Due to the poor state of preservation of long bones, it was not possible to reconstruct his stature. No palaeopathological lesions were observed.

Barrow 1, feature 7



The pit fill contained the human skeletal remains of three individuals.

Skeleton 1. A poorly-preserved skeleton with a badly damaged skull. The preserved bones include small fragments of the cranial vault and two fragments of the femur. The skeleton belonged to a male aged 35-55 years (*maturus*). Due to the poor state of preservation of long bones, it was not possible to reconstruct his stature. No palaeopathological lesions were observed.

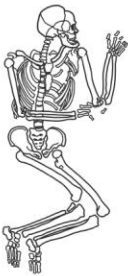

Skeleton 2. A poorly-preserved skeleton with a badly damaged skull. The preserved bones include small fragments of the skull and upper and lower limbs. The skeleton belonged to a child aged 4-5 years (*infans I*). No palaeopathological lesions were observed.

Skeleton 3. A poorly-preserved skeleton with a badly damaged skull. The preserved bones include large fragments of lower limbs. The skeleton most probably belonged to a female aged 35-55 years (*maturus*). Due to the poor state of preservation of long bones, it was not possible to reconstruct her stature.

Palaeopathological lesions: extreme lowering of alveolar processes.

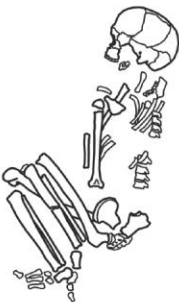
Barrow 1, feature 11



A well-preserved skeleton with a badly damaged skull. The preserved bones include small fragments of the skull, upper and lower limbs, the pelvis and a foot. The skeleton belonged to a male aged 20-25 years (*adultus*). The molecular analysis not corroborated the morphological sex assessment. The stature of the individual was approx. 174 cm.

Palaeopathological lesions: dental calculus, Schmorl's nodes on thoracic vertebrae, degenerative lesions of the proximal end of the 1st metatarsal bone.

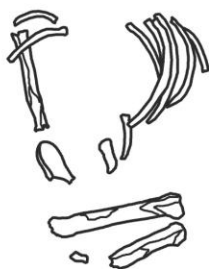
Barrow 1, feature 12



A very poorly-preserved skeleton with a badly damaged skull. The preserved bones include small fragments of the skull and upper and lower limbs, as well as small fragments of the pelvis. The skeleton belonged to a child aged 12-14 years (*infans II*). The results of molecular analysis implied this individual to be female.

Palaeopathological lesions: LEH on the upper right second premolar (age of the individual at the time of defect: 4.5-5.0 years).

Barrow 1, feature 13



A very poorly-preserved skeleton: only small fragments of long bones (femur and tibia) were recorded. The skeleton belonged to an adult. Due to the poor state of bone preservation, it was not possible to reconstruct the individual's stature nor estimate his or her age nor determine sex. No palaeopathological lesions were observed.

Table 4

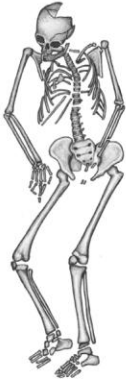Basic information on skeletal material from Barrow 1, Klembivka site

Site	Grave	Anthropological Age Determination	Anthropological Sex Assignment	Molecular Sex Assignment	Archaeological Culture
Klembivka 1	Feature 2	Adult (20+ years)	?	Not done	BC
Klembivka 1	Feature 3	<i>Maturus</i> (35-45 years)	Male	Not done	BC
Klembivka 1	Feature 5	<i>Maturus</i> (50-55 years)	Male	Not done	Eneolithic
Klembivka 1	Feature 7 skeleton 1	<i>Maturus</i> (35-55 years)	Male	Not done	NC
Klembivka 1	Feature 7 skeleton 2	<i>Infans I</i> (4-5 years)	---	Not done	NC
Klembivka 1	Feature 7 skeleton 3	<i>Adultus/maturus</i> (20-55 years)	Female?	Not done	NC
Klembivka 1	Feature 11	<i>Adultus</i> (20-25 years)	Male	XX	NC
Klembivka 1	Feature 12	<i>Infans II</i> (12-14 years)	---	XX	NC
Klembivka 1	Feature 13	Adult (+20 years)	?	Not done	NC
Klembivka 1	Feature 14	<i>Adultus</i> (25-30 years)	Male	Not done	Eneolithic
Klembivka 1	Feature 15	<i>Juvenis</i> (15-20 years)	---	Not done	Eneolithic

From the Prydnistryanske site 1, skeletal material belonging to 17 individuals were recovered: 14 adults and 3 children (Tab. 5) [Klochko *et al* 2015].

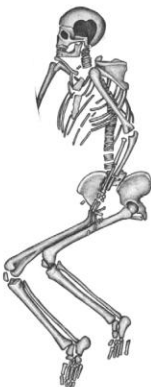3.4.1. BARROW I

3.4.1.1. CATACOMB CULTURE BURIALS

Feature I/4, skeleton 1

A poorly-preserved skeleton with a badly damaged skull. The following skull bones or their fragments were preserved: frontal bone, occipital bone, sphenoid bone, mandible, parietal bones, temporal bones, zygomatic bones, maxillary bones. The postcranial skeleton was represented by the following bones or their fragments: clavicles, scapulae, patellae, sternum, ilia, ischia, pubis, sacrum, vertebrae, ribs, humeri, ulnae, radii, femora, tibiae, fibulae, hand and foot bones. The skeleton belonged to an adolescent aged about 15 years (*ju-venis*). The results of molecular analysis implied this individual to be male.

Palaeopathological lesions: LEH on both lower medial incisors (age of the individual at the time of both defects: 2.0-2.5 years).

Feature I/4, skeleton 2

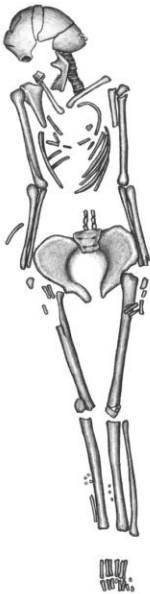A well-preserved skeleton with a badly damaged skull. The following skull bones or their fragments were preserved: frontal bone, occipital bone, sphenoid bone, mandible, parietal bones, temporal bones, zygomatic bones, maxillary bones and left palatine bone. The postcranial skeleton was represented by the following bones or their fragments: clavicles, scapulae, patellae, sternum, ilia, ischia, pubis, sacrum, vertebrae, ribs, humeri, ulnae, radii, femora, tibiae, fibulae, hand and foot bones. The skeleton most probably belonged to a male aged 35-50 years (*maturus*). The results of molecular analysis implied this individual to be female. The stature of the individual was approx. 165 cm.

Palaeopathological lesions: osteophytes on three lumbar vertebrae; ossified ligaments on both patellae and both calcanei (enthesopathy).

3.4.1.2. IRON AGE BURIALS

Feature I/2

A very poorly-preserved skeleton. The following bones or their fragments were recorded: right maxilla, left zygomatic bone, vertebrae, right ilium, right femur. The skeleton belonged to a child aged about 4 years (*infans I*). No palaeopathological lesions were observed.

Feature I/3

A poorly-preserved skeleton with a badly damaged skull. The following skull bones or their fragments were preserved: frontal bone, occipital bone, sphenoid bone, mandible, both parietal bones, temporal bones, right zygomatic bone, maxillary bones, right palatine bone. The postcranial skeleton was represented by the following bones or their fragments: clavicles, scapulae, patellae, ilia, ischia, pubis, sacrum, vertebrae, ribs, humeri, ulnae, radii, femora, tibiae, fibulae, hand and foot bones. The skeleton belonged to a female aged 45-55 years (*maturus*). The stature of the individual was approx. 162 cm.

Palaeopathological lesions: degenerative lesions of the spinal column (spondylosis) observable on three cervical vertebrae (C3-5); caries of the right upper first molar, lower left first molar, lower left second molar; upper right second molar, upper left second premolar, upper left first molar, upper left second molar, lower right second premolar were lost *antemortem*.

3.4.2. BARROW II

3.4.2.1. ENEOLITHIC BURIAL

Feature III/1

A very poorly-preserved skeleton. The following bones or their fragments were recorded: a vertebra, metacarpals, and ilium. The skeleton must have belonged to an adult. Due to the poor state of bone preservation, it was not possible to reconstruct the individual's stature nor estimate his or her age-at-death nor determine sex. No palaeopathological lesions were observed.

3.4.2.2. BURIAL OF AN INDETERMINATE CHRONOLOGY

Feature II/3

A very poorly-preserved skeleton. Only very fine fragments of human bones were recorded. The skeleton must have belonged to an adult. Due to the poor state of bone preservation, it was not possible to reconstruct the individual's stature nor estimate his or her age-at-death nor determine sex. No palaeopathological lesions were observed.

3.4.3. BARROW III

3.4.3.1. ENEOLITHIC BURIALS


Feature III/1



A very poorly-preserved skeleton. The following bones or their fragments were recorded: the sternum, ribs, scapulae, vertebrae, ulnae, femora, left ischium, left pubic bone, sacrum, carpal bones, tarsals, metacarpals, metatarsals, phalanges. The skeleton belonged to an adult. Due to the poor state of bone preservation, it was not possible to reconstruct the individual's stature nor estimate his or her age-at-death nor determine sex.

Palaeopathological lesions: healed fracture of the left ulna; block of two thoracic vertebrae, osteophytes on cervical and thoracic vertebrae.

Feature III/2



Very poorly-preserved skeletal material. The following bones or their fragments were recorded: the sternum, ribs, scapula, vertebrae, femora, fibulae, tibia, right patella, carpals, metacarpals, tarsals, metatarsals, phalanges. The skeletal material belonged to two individuals: a child aged 9-10 years (*infans II*) and an adult. Due to the poor state of bone preservation, it

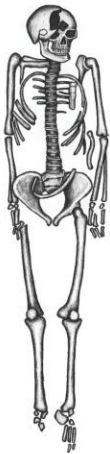was not possible to reconstruct the adult individual's stature nor estimate his or her age nor determine sex. No palaeopathological lesions were observed.

Feature III/3

Very poorly-preserved skeletal material. Only a small fragment of a human bone, belonging to an adult, was recorded. Due to the poor state of bone preservation, it was not possible to reconstruct the individual's stature nor estimate his or her age-at-death nor determine sex. No palaeopathological lesions were observed.

3.4.3.2. IRON AGE BURIAL

Feature III/4



A poorly-preserved skeleton with a badly damaged skull. The following skull bones or their fragments were preserved: frontal bone, occipital bone, sphenoid bone, mandible, parietal bones, temporal bones, left zygomatic bone, maxillary bones, left palatine bone. The postcranial skeleton was represented by the following bones or their fragments: clavicles, scapulae, patellae, sternum, ilia, ischia, pubic bones, sacrum, vertebrae, ribs, humeri, right ulna, radii, femora, tibiae, fibulae, hand and foot bones. The skeleton belonged to a male aged 30-40 years (*adultus/maturus*). The stature of the individual was approx. 169 cm.

Palaeopathological lesions: caries of the upper right third molar, lower right second molar, lower right first molar and lower left first molar; telltale wearing of the tooth crowns due to occupational stress of the upper right second premolar (distal surface) and upper right first molar (mesial surface); lower left second molar and lower left third molar were lost *antemortem*; osteophytes were recorded on two thoracic (Th9-10) and two lumbar (L4-5) vertebrae.

3.4.4. BARROW IV

3.4.4.1. ENEOLITHIC BURIAL

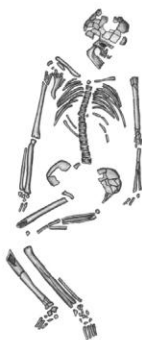Feature IV/10

A very poorly-preserved skeleton of an adult. The following bones or their fragments were recorded: skull bones, a rib, vertebra, carpals, tarsals, metatarsals, phalanges. Due to the poor state of bone preservation, it was not possible to recon-

struct the individual's stature nor estimate his or her age-at-death nor determine sex. No palaeopathological lesions were observed.

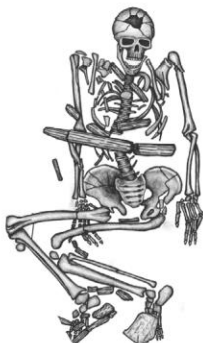3.4.4.2. YAMNAYA CULTURE

Feature IV/3



A very poorly-preserved skeleton with a badly damaged skull. The following skull bones or their fragments were preserved: frontal bone, occipital bone, mandible, parietal bones, temporal bones. The postcranial skeleton was represented by the following bones or their fragments: scapulae, patellae, ilia, pubic bones, sacrum, vertebrae, ribs, humeri, right radius, right ulna, femora, tibiae, fibulae, hand and foot bones. The skeleton belonged to an adult aged over 40 years (*maturus/senilis*). Due to the poor state of bone preservation, it was not possible to reconstruct the individual's stature nor determine his or her sex. No palaeopathological lesions were observed.

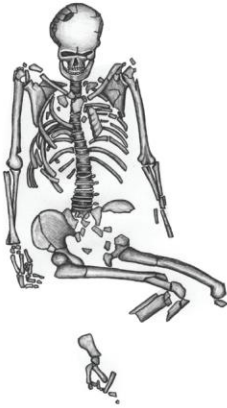
Feature IV/4



A well-preserved skeleton with a badly damaged skull. The following skull bones or their fragments were preserved: frontal bone, occipital bone, sphenoid bone, mandible, parietal bones, temporal bones, zygomatic bones, and maxillae. The postcranial skeleton was represented by the following bones or their fragments: clavicles, right scapula, patellae, sternum, ilia, ischia, pubic bones, sacrum, vertebrae, ribs, humeri, ulnae, radii, femur, tibiae, fibulae, hand and foot bones. The skeleton belonged to a male aged 35-50 years (*maturus*). The molecular analysis corroborated the morphological sex assessment. The stature of the individual was approx. 187 cm.

Palaeopathological lesions: osteoarthritis of the left carpals (scaphoid, lunate, triquetrum, capitate, trapezoid, hamate), sternal ends of the left and right clavicle, right clavicular notch of the manubrium sterni, articular surfaces of both scapulae, head of the left humerus, articular surface of the distal end of the left radius, articular surface of the distal end of the right ulna and articular surface of the distal end of the right radius. These lesions are related to the individual's great physical activity and the mechanical stress he must have been subjected to [Molnar *et al.* 2011; Weiss, Jurmain 2007]. Other lesions include: blocks of cervical vertebrae (C1-2 and C3-4), spondylosis of two cervical and five thoracic vertebrae, and of the fifth lumbar vertebra (L-5) and the base of the sacrum; Schmorl's nodes on the first thoracic vertebra; osteophytes on three lumbar vertebrae; ossified ligaments (enthesopathy) on the right calcaneus.

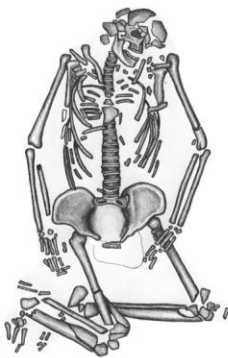
Feature IV/6



A poorly-preserved skeleton with a badly damaged skull. The following skull bones or their fragments were preserved: frontal bone, occipital bone, sphenoid bone, mandible, parietal bones, temporal bones, zygomatic bones, maxillary bones. The postcranial skeleton was represented by the following bones or their fragments: clavicles, scapulae, patellae, sternum, ilia, left ischium, pubic bones, vertebrae, ribs, humeri, ulnae, radii, femora, tibiae, right fibula, hand and foot bones. The skeleton belonged to a male aged above 45 years (*maturus/senilis*). Due to the poor state of preservation of long bones, it was not possible to reconstruct his stature.

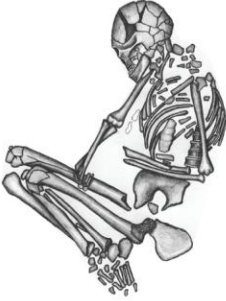Palaeopathological lesions: lower left medial incisor was lost *antemortem*; telltale wearing of the tooth crowns, due to occupational stress, of the upper right third molar (mesial surface), upper right second molar (distal surface), upper right first molar (mesial and distal surfaces), upper right second premolar (distal surface), upper right first premolar (distal surface), lower left second premolar (distal surface), lower right second premolar (distal surface), lower right first molar (mesial and distal surfaces), lower right second molar (distal surface); osteophytes on three fragments of vertebra bodies; ossified ligaments (enthesopathy) on both patellae.

Feature IV/8



A poorly-preserved skeleton with a badly damaged skull. The following skull bones or their fragments were preserved: frontal bone, occipital bone, sphenoid bone, mandible, parietal bones, temporal bones, zygomatic bones, maxillae. The postcranial skeleton was represented by the following bones or their fragments: clavicles, scapulae, patellae, sternum, ilia, ischia, pubic bones, sacrum, vertebrae, ribs, humeri, ulnae, radii, femora, tibiae, fibulae, hand and foot bones. The skeleton belonged to a male aged 35-50 years (*maturus*). Due to the poor state of preservation of long bones, it was not possible to reconstruct his stature.

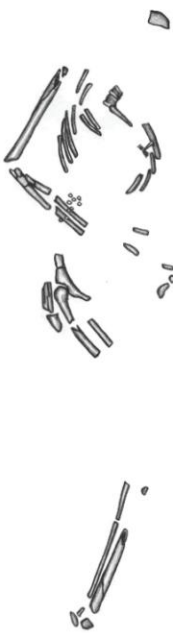Palaeopathological lesions: Schmorl's nodes on four thoracic vertebrae; *cribra orbitalia* (1st degree on the GHHP 2006 scale, type: healed) on the right orbital roof; ossified ligaments (enthesopathy) on both patellae.

Feature IV/9

A poorly-preserved skeleton with a badly damaged skull. The following skull bones or their fragments were preserved: frontal bone, occipital bone, sphenoid bone, mandible, parietal bones, temporal bones, right zygomatic bone, maxillary bone. The postcranial skeleton was represented by the following bones or their fragments: clavicles, scapulae, patellae, sternum, ilia, ischia, pubic bones, vertebrae, ribs, humeri, ulnae, radii, femora, tibiae, fibulae, hand and foot bones. The skeleton belonged to a male aged 25-35 years (*adultus*). The molecular analysis corroborated the morphological sex assessment. Due to the poor state of preservation of long bones, it was not possible to reconstruct his stature.

Palaeopathological lesions: osteoarthritis on the sternal end of the left clavicle. These lesions are related to the individual's great physical activity and the mechanical stress he must have been subjected to [Molnar *et al.* 2011, Weiss, Jurmain 2007]. Schmorl's nodes were recorded on two vertebrae.

3.4.4.3. IRON AGE BURIAL

Feature IV/1

A poorly-preserved skeleton. The following bones or their fragments were recovered: occipital bone, left femur, fibula, hand phalanx, as well numerous fragments of the shafts and epiphyses of long bones. The skeleton belonged to an adult. Due to the poor state of bone preservation, it was not possible to reconstruct the individual's stature nor estimate his or her age-at-death nor determine sex. No palaeopathological lesions were observed.

Table 5

Basic information on skeletal material from the Prydnistryanske site

Site	Grave	Anthropological Age Determination	Anthropological Sex Assignment	Molecular Sex Assignment	Archaeological Culture
Prydnistryanske 1	I/2	<i>Infans I</i> (about 4 years)	---	Not done	Iron Age
Prydnistryanske 1	I/3	<i>Maturus</i> (45-55 years)	Female	Not done	Iron Age
Prydnistryanske 1	I/4S1	<i>Juvenis</i> (14-15 years)	---	XY	CC
Prydnistryanske 1	I/4S2	<i>Maturus</i> (35-50 years)	Male?	XX	CC
Prydnistryanske 1	II/3	<i>Adultus</i> (20+ years)	?	Not done	Iron Age
Prydnistryanske 1	III/1	<i>Adultus</i> (20+ years)	?	Not done	Eneolithic
Prydnistryanske 1	III/2S1	<i>Adultus</i> (20+ years)	?	Not done	Eneolithic
Prydnistryanske 1	III/2S2	<i>Infans II</i> (9-10 years)	---	Not done	Eneolithic
Prydnistryanske 1	III/3	<i>Adultus</i> (20+ years)	?	Not done	Eneolithic
Prydnistryanske 1	III/4	<i>Adultus/maturus</i> (30-40 years)	Male	Not done	Iron Age
Prydnistryanske 1	IV/1	<i>Adultus</i> (20+ years)	?	Not done	Iron Age
Prydnistryanske 1	IV/3	<i>Maturus/senilis</i> (+40 years)	?	Not done	YC
Prydnistryanske 1	IV/4	<i>Maturus</i> (35-50 years)	Male	XY	YC
Prydnistryanske 1	IV/6	<i>Maturus/senilis</i> (45+ years)	Male	Not done	YC
Prydnistryanske 1	IV/8	<i>Maturus</i> (35-50 years)	Male	Not done	YC
Prydnistryanske 1	IV/9	<i>Adultus</i> (25-35 years)	Male	XY	YC
Prydnistryanske 1	IV/10	<i>Adultus</i> (20+ years)	?	Not done	Eneolithic

Table 6

Frequencies of health status indicators

Site	Age	CO			HP			LEH ¹			Caries ¹		
		N	n	%	N	n	%	N	n	%	N	n	%
Pidlisivka 1	Subadult	2	0	0.0	1	0	0.0	2	1	50.0	2	0	0.0
	Adult	3	0	0.0	3	0	0.0	6	3	50.0	7	1	14.3
	Total	5	0	0.0	4	0	0.0	8	4	50.0	9	1	11.1
Klembivka 1	Subadult	1	0	0.0	1	0	0.0	2	1	50.0	2	0	0.0
	Adult	4	0	0.0	2	1	50.0	2	0	0.0	5	2	40.0
	Total	5	0	0.0	3	1	33.3	4	1	25.0	7	2	28.6
Porohy 3A	Subadult	2	1	50.0	0	0	0.0	0	0	0.0	0	0	0.0
	Adult	5	0	0.0	2	1	50.0	4	1	25.0	5	1	20.0
	Total	7	1	14.3	2	1	50.0	4	1	25.0	5	1	20.0
Prydnistryanske 1	Subadult	1	0	0.0	0	0	0.0	1	1	100.0	1	0	0.0
	Adult	6	1	16.7	2	0	0.0	4	0	0.0	8	2	25.0
	Total	7	1	14.3	2	0	0.0	5	1	20.0	9	2	22.2

¹ data for permanent teeth; N – number of individuals included in the study; n – number of individuals in whom a given indicator was observed; % – percentage of individuals in whom a given indicator was observed

4. SUMMARY

4.1. STATE OF HEALTH ANALYSIS

For the purpose of evaluating the status of health of the human population under investigation, the following indicators were used: linear enamel hypoplasia (LEH), *cribra orbitalia* (CO), porotic hyperostosis (PH) and dental caries. Table 6 presents the frequencies of indicators for individual sites divided into adults and children.

In the studied group, LEH was observed in 7 among 21 individuals whose permanent teeth were available for examination, which represents 33.33 per cent. LEH indicates nutrient deficiencies and infectious diseases in early childhood [Goodman *et al.* 1980; Lanphear 1990]. In turn, the reconstruction of the time when hypoplastic defects occurred informs about the period when the child was particularly exposed to detrimental environmental factors. In the studied group the

Table 7

Incidence of state of health indicators divided into archaeological cultures

Culture/Age	Enolithic		YC		BC		CC		NC		IA		?	
	N	%	N	%	N	%	N	%	N	%	N	%	N	%
CO	1	0.0	1	0.0	1	0.0	1	0.0	0	0.0	0	0.0	1	0.0
	0	0.0	7	14.3	0	0.0	0	0.0	0	0.0	0	0.0	0	0.0
	2	0.0	0	0.0	0	0.0	1	0.0	2	0.0	0	0.0	0	0.0
	0	0.0	4	25.0	2	0.0	0	0.0	0	0.0	0	0.0	1	0.0
HP	0	0.0	1	0.0	0	0.0	1	0.0	0	0.0	0	0.0	1	0.0
	0	0.0	2	50.0	0	0.0	0	0.0	0	0.0	0	0.0	0	0.0
	1	100.0	0	0.0	0	0.0	0	0.0	2	0.0	0	0.0	0	0.0
	0	0.0	0	0.0	1	0.0	0	0.0	0	0.0	0	0.0	1	0.0
LEH*	1	100.0	1	0.0	2	100.0	2	100.0	2	50.0	0	0.0	1	0.0
	0	0.0	4	25.0	0	0.0	0	0.0	0	0.0	0	0.0	0	0.0
	2	0.0	0	0.0	0	0.0	0	0.0	2	50.0	0	0.0	0	0.0
	0	0.0	3	0.0	1	100.0	0	0.0	0	0.0	0	0.0	1	0.0
Caries*	1	0.0	2	0.0	2	0.0	2	0.0	0	0.0	0	0.0	1	100.0
	0	0.0	4	25.0	0	0.0	0	0.0	1	0.0	1	0.0	0	0.0
	3	66.7	0	0.0	0	0.0	1	0.0	3	0.0	0	0.0	0	0.0
	0	0.0	5	0.0	2	50.0	0	0.0	0	0.0	2	50.0	0	0.0

* data for permanent teeth; N – number of individuals included in the study; n – number of individuals in whom a given indicator was observed;
% – percentage of individuals in whom a given indicator was observed

largest number of defects occurred at the ages of 2.5-3.0 and 4.5-5.0. It was at these ages that young individuals were subjected to the strongest stressors.

In the examined skeletal material, *cribra orbitalia* was observed only in 2 out of 24 individuals included in the study (8.3%). These lesions are believed to be related to various types of anaemia (resulting, for instance, from iron deficiency in food). The low value of this stress indicator may show that the population under investigation did not suffer much from iron deficiency in their diet. This view is supported by a relatively low incidence of porotic hyperostosis (19%). These lesions, similarly to *cribra orbitalia*, are identified with bone marrow hypertrophy caused by anaemia [Cohen, Armelagos 1984].³

Out of 30 examined individuals having permanent teeth, 6 were found to have had caries (20%). In the population under investigation, caries was recorded on 11 out of 553 teeth (4.5%). Carious defects are commonly linked to a sugar-rich diet. Higher caries incidence is attributed to the consumption of carbohydrate-rich foods, while its low incidence is commonly associated with a sugar-poor diet.⁴ The small number of individuals with caries suggests that the examined population may have subsisted on a diet of largely animal-derived food [Turner 1979].

Table 7 shows the incidence of individual state of health indicators divided according to the cultural affiliation of individuals. *Cribrā orbitalia* was found only in the representatives of the Yamnaya culture (n=2, N=12). Porotic hyperostosis was found in the individuals of the Endolithic (n=1, N=1) and YC (n=1, N=3). LEH on permanent teeth was found in Endolithic individuals (n=1, N=3), YC (n=1, N=8), CC ones (n=3, N=3), BC ones (n=1, N=2) and NC (n=1, N=2). Tooth caries on permanent teeth was recorded in the individuals of the Eneolithic (n=2, N=4), YC (n=1, N=11), CC (n=1, N=4) and those dated to the Iron Age (n=2, N=3). Unfortunately, it cannot be determined if there were any statistically significant differences between the state of health of individuals representing various archaeological cultures due to the meagreness of materials available for examination.

³ More recent research shows that such lesions may also result from nutrient deficiencies (vitamins B12, B6, C, D, and folic acid), parasite activity or diarrhoea [Lallo *et al.* 1977; Mensforth *et al.* 1978; Facchini *et al.* 2004; Cucina *et al.* 2006; Walker *et al.* 2009].

⁴ This is a result of the fact that microorganisms found in the dental plaque, when they metabolize carbohydrates, produce organic acids which, in turn, lower the pH of the mouth. This damages tooth tissues and brings about caries [Powel 1985; Šlaus *et al.* 2010]. Whereas populations relying for their diet on animal-derived food are characterized by a low incidence of carious defects, because proteins and calcium contained in it protects teeth against their development [Pedersen 1938; Turner 1979; Walker, Erlandson 1982].

4.2. MOLECULAR EXAMINATIONS

Molecular sex determination. Examinations were performed on individuals chronologically related to the 4th/3rd and 2nd millennia BC. We were able to confidently determine molecular sex for 10 specimens involving two individuals from Pidlisivka 1, two individuals from Porohy 3A, two individuals from Klembivka 1 and four individuals from Prydnistryanske 1 (*see* Table 1 for locations and Table 2-5 for results). Estimated R_y values were lower than 0.016 in females and higher than 0.075 in males [Skoglund *et al.* 2013]. For each individual, molecular sex identification was in accordance with anthropological determinations (Pidlisivka 1/16, Porohy 3A/12 skeleton 1, Prydnistryanske I/4 and Prydnistryanske I/4 skeleton 2). For additional two individuals, molecular sex identification strengthened previous uncertain morphological assessments (Pidlisivka Feature 13 and Prydnistryanske I/4 skeleton 2). In three cases, two 12-15 year-old-children and an adult, sex was estimated solely by molecular analyses (Klembivka 1/12, Porohy 3A/20 skeleton 2 and Prydnistryanske I/4 skeleton 1). The state of bone preservation was very poor among these individuals. The two sex assessment methods gave contradicting results for one individual (Klembivka 1/11). This type of discordance between the methods has been noticed also in other studies [eg. Skoglund *et al.* 2013, Allentoft *et al.* 2015, Mathieson *et al.* 2015]. Varying degrees of bone preservation in diagnostic bone elements and differences between modern reference populations and the ancient populations investigated, could, for example result in morphological misclassifications [Kjellström 2004].

CONCLUSIONS

Health status indicators were recorded in a relatively small number of individuals among those included in the study, which could indicate their relatively good health and confirm that the community in question relied chiefly on animal products for their diet. However, it must be noted that the meagreness of the skeletal material, its poor state of preservation as well as the broad chronological range, prevent us from drawing any definite conclusions at this stage of research.

Building a complete picture of the biological structure of the Yamnaya culture community calls for further research. Only a greater number of analyzed individuals will make any firm conclusions concerning the community possible.

Molecular sex determination is an important complement to the anthropological sex assessments. This is especially true for young individuals that can be difficult to determine morphologically as well as for individuals that lack preserved diagnostic features. Although next-generation sequencing is costly in general, quite little sequence data is needed for molecular sex determination purposes.

SUPPLEMENT 1

Number of individuals studied from to the Eneolithic and Bronze Age

Site	Children		Adults		Total	
	N	%	N	%	N	%
Pidlisivka 1	6	35.3	6	15.0	12	22.2
Klembivka 1	3	17.6	8	20.0	11	20.4
Porohy 3A	5	29.4	14	35.0	19	35.2
Prydnistryan-ske 1	2	11.8	10	58.9	12	22.2
Total	16	29.6	38	70.4	54	100.0

SUPPLEMENT 2

Basic information for antropological description

	Archaeological site	Grave	Age	CO	HP	LEH	Car-ies
1	Pidlisivka 1	Barrow 1 Mound	<i>Subadult</i>	+	+	+	+
2	Pidlisivka 1	Barrow 1 Feature 1a Skeleton 1	<i>Subadult</i>	-	-	-	-
3	Pidlisivka 1	Barrow 1 Feature 1a Skeleton 2	<i>Adult</i>	-	-	-	+
4	Pidlisivka 1	Barrow 1 Feature 1b	<i>Adult</i>	-	-	+	+
5	Pidlisivka 1	Barrow 1 Feature 4	<i>Subadult</i>	-	-	+	+
6	Pidlisivka 1	Barrow 1 Feature 5	<i>Adult</i>	+	-	+	+
7	Pidlisivka 1	Barrow 1 Feature 7	<i>Adult</i>	+	-	+	+
8	Pidlisivka 1	Barrow 1 Feature 8	<i>Subadult</i>	-	-	-	-
9	Pidlisivka 1	Barrow 1 Feature 9	<i>Subadult</i>	-	-	-	-
10	Pidlisivka 1	Barrow 1 Feature 10	<i>Subadult</i>	+	-	-	-
11	Pidlisivka 1	Barrow 1 Feature 11	<i>Adult</i>	+	+	+	+
12	Pidlisivka 1	Barrow 1 Feature 12	<i>Adult</i>	-	+	+	+
13	Pidlisivka 1	Barrow 1 Feature 13	<i>Adult</i>	-	+	+	+
14	Klembivka 1	Barrow 1 Feature 2	<i>Adult</i>	-	-	-	-
15	Klembivka 1	Barrow 1 Feature 3	<i>Adult</i>	+	-	-	+

16	Klembivka 1	Barrow 1 Feature 5	<i>Adult</i>	+	-	-	+
17	Klembivka 1	Barrow 1 Feature 7 Skeleton 1	<i>Adult</i>	-	-	-	-
18	Klembivka 1	Barrow 1 Feature 7 Skeleton 2	<i>Subadult</i>	-	-	-	-
19	Klembivka 1	Barrow 1 Feature 7 Skeleton 3	<i>Adult</i>	-	-	-	+
20	Klembivka 1	Barrow 11 Feature 11	<i>Adult</i>	+	+	+	+
21	Klembivka 1	Barrow 1 Feature 12	<i>Subadult</i>	+	+	+	+
22	Klembivka 1	Barrow 1 Feature 13	<i>Adult</i>	-	-	-	-
23	Klembivka 1	Barrow 1 Feature 14	<i>Adult</i>	+	+	+	+
24	Klembivka 1	Barrow 1 Feature 15	<i>Subadult</i>	-	-	+	+
25	Porohy 3A	Barrow 3 Feature 1	<i>Adult</i>	-	-	-	-
26	Porohy 3A	Barrow 3 Feature 2	<i>Adult</i>	-	-	-	-
27	Porohy 3A	Barrow 3 Feature 3	<i>Subadult</i>	-	-	-	-
28	Porohy 3A	Barrow 3 Feature 5	<i>Adult</i>	-	-	-	-
29	Porohy 3A	Barrow 3 Feature 7	<i>Adult</i>	-	-	-	+
30	Porohy 3A	Barrow 3 Feature 8	<i>Adult</i>	-	-	-	-
31	Porohy 3A	Barrow 3 Feature 10	<i>Adult</i>	+	+	+	+
32	Porohy 3A	Barrow 3 Feature 11	<i>Adult</i>	+	-	+	+
33	Porohy 3A	Barrow 3 Feature 12 Skeleton 1	<i>Adult</i>	+	+	+	+
34	Porohy 3A	Barrow 3 Feature 12 Skeleton 2	<i>Subadult</i>	+	-	-	-
35	Porohy 3A	Barrow 3 Feature 2/14	<i>Subadult</i>	-	-	-	-
36	Porohy 3A	Barrow 3 Feature 2/14	<i>Adult</i>	-	-	-	-
37	Porohy 3A	Barrow 3 Feature 15	<i>Adult</i>	+	-	+	+
38	Porohy 3A	Barrow 3 Feature 17	<i>Adult</i>	+	-	-	-
39	Porohy 3A	Barrow 3 Feature 18	<i>Subadult</i>	-	-	-	-
40	Porohy 3A	Barrow 3 Feature 19	<i>Subadult</i>	+	-	-	-
41	Porohy 3A	Barrow 3 Feature 20 Skeleton 1	<i>Adult</i>	-	-	-	-
42	Porohy 3A	Barrow 3 Feature 20 Skeleton 2	<i>Adult</i>	-	-	-	-
43	Porohy 3A	Barrow 3 Feature 21	<i>Adult</i>	-	-	-	-
44	Porohy 3A	Barrow 3 Feature 22	<i>Adult</i>	-	-	-	-
45	Prydnistryanske 1	Barrow 1 Feature 2	<i>Subadult</i>	-	-	-	-
46	Prydnistryanske 1	Barrow 1 Feature 3	<i>Adult</i>	+	+	-	+
47	Prydnistryanske 1	Barrow 1 Feature 4 Skeleton 1	<i>Subadult</i>	+	-	+	+

48	Prydnistryanske 1	Barrow 1 Feature 4 Skeleton 2	<i>Adult</i>	+	+	-	+
49	Prydnistryanske 1	Barrow 2 Feature 3	<i>Adult</i>	-	-	-	-
50	Prydnistryanske 1	Barrow 3 Feature 1	<i>Adult</i>	-	-	-	-
51	Prydnistryanske 1	Barrow 3 Feature 2 Skeleton 1	<i>Adult</i>	-	-	-	-
52	Prydnistryanske 1	Barrow 3 Feature 2 Skeleton 2	<i>Subadult</i>	-	-	-	-
53	Prydnistryanske 1	Barrow 3 Feature 3	<i>Adult</i>	-	-	-	-
54	Prydnistryanske 1	Barrow 3 Feature 4	<i>Adult</i>	-	-	+	+
55	Prydnistryanske 1	Barrow 4 Feature 1	<i>Adult</i>	-	-	-	-
56	Prydnistryanske 1	Barrow 4 Feature 3	<i>Adult</i>	+	-	-	+
57	Prydnistryanske 1	Barrow 4 Feature 4	<i>Adult</i>	+	-	+	+
58	Prydnistryanske 1	Barrow 4 Feature 6	<i>Adult</i>	+	-	-	+
59	Prydnistryanske 1	Barrow 4 Feature 8	<i>Adult</i>	+	-	+	+
60	Prydnistransk	Barrow 4 Feature 9	<i>Adult</i>	-	-	+	+
61	Prydnistryanske 1	Barrow 4 Feature 10	<i>Adult</i>	-	-	-	-
Total				23	11	21	30

Translated by Piotr T. Żebrowski

REFERENCES

Allentoft M.E., Sikora M., Sjögren K.G., Rasmussen S., Rasmussen M., Stenderup J., Damgaard P.B., Schroeder H., Ahlström T., Vinner L., Malaspinas A.S., Margaryan A., Higham T., Chivall D., Lynnerup N., Harvig L., Baron J., Della Casa P., Dąbrowski P., Duffy P.R., Ebel A.V., Epimakhov A., Frei K., Furmanek M., Gralak T., Gromov A., Gronkiewicz S., Grupe G., Hajdu T., Jarysz R., Khartanovich V., Khokhlov A., Kiss V., Kolář J., Kriiska A., Lasak I., Longhi C., Mc Glynn G., Merkevicus A., Merkyte I., Metspalu M., Mkrtchyan R., Moiseyev V., Paja L., Pálfi G., Pokutta D., Pospieszny Ł., Price T.D., Saag L., Sablin M., Shishlina N., Smrčka V., Soenov V.I., Szeverényi V., Tóth G., Trifanova S.V., Varul L., Vicze M., Yepiskoposyan L., Zhitenev V., Orlando L., Slicheritz-Pontén P., Brunak S., Nielsen R., Kristiansen K., Willerslev E.

2015 Population genomics of Bronze Age Eurasia. *Nature* 522(7555): 167-172.

Anthon D.W.

2007 *The Horse, the Wheel, the Language: How Bronze-Age Riders from the Eurasian Steppes the Modern World*. Oxford.

Baker B.J., Dupras T.L., Tocheri M.W.

2005 *The Osteology of Infants and Children*. College Station. Texas.

Bednarek R., Hildebrandt-Radke I., Jankowski M., Juras A., Koško A., Langer J., Makohonienko M., Pietrzak S., Razumow S., Sikorski A., Żurkiewicz D.

2014 Charakterystyka źródeł archeologicznych i przyrodniczych z kurhanu Pidlisivka 1 (badania z roku 2010). In: A. Koško, M. Potupczyk, S. Razumow (Eds), *Naddniestrzańskie kompleksy cmentarzysk kurhanowych społeczności z III i z pierwszej połowy II tysiąclecia przed Chr. w okolicach Jampola, obwód winnicki. Z badań nad północno-zachodnią rubieżą osadnictwa społeczności kręgu kultur „wczesnobrzązowych” strefy pontyjskiej. Badania z lat 1984-2014*. *Archaeologia Bimaris – Monografie* 6, 205-297. Poznań.

Buikstra J.E., Ubelaker D.H.

1994 Standards for data collection from human skeletal remains. Proceedings of a seminar at the field Museum of Natural History. *Arkansas Archaeological Survey Research Series* 44. Arkansas.

Cohen M.N., Armelagos G.J.

1984 *Paleopathology at the Origins of Agriculture*. Florida.

Cucina A.

- 2002 Brief communication: diachronic investigation of linear enamel hypoplasia in prehistoric skeletal samples from Trentino, Italy. *American Journal of Physical Anthropology* 119(3): 283-7.

Facchini F., Rastelli E., Brasili P.

- 2004 Cribra orbitalia and cribra cranii in Roman skeletal remains from the Ravenna area and Rimini (I–IV century AD). *International Journal of Osteoarchaeology* 14(2): 126-136.

Goodman A.H., Armelagos G.J., Rose J.C.

- 1980 Enamel hypoplasias as indicators of stress in three prehistoric populations from Illinois. *Human Biology* 52(3): 515-528.

Goodman A.H., Rose J.C.

- 1990 Assessment of systemic physiological perturbation from dental enamel hypoplasias and associated histological structures. *American Journal of Physical Anthropology* 33: 59-110.

Goslar T., Klochko V.I., Koško A., Włodarczak P., Żurkiewicz D.

- 2015 Chronometry of Late Eneolithic and ‘Early Bronze’ cultures in the Middle Dniester area: investigations of the Yampil Barrow Complex. In: A. Koško (Ed.). *Podolia as a Cultural Contact Area in the 4th/3rd-2nd Millennium BC. Baltic-Pontic Studies* 20: 256-291.

Günther T., Valdiosera C., Malmström H., Ureña I., Rodriguez-Varela R., Sverrisdóttir Ó.O., Daskalaki E.A., Skoglund P., Naidoo T., Svensson E.M., Bermúdez de Castro J.M., Carbonell E., Dunn M., Storå J., Iriarte E., Arsuaga J.L., Carretero J. M., Götherström A., Jakobsson M.

- 2015 Ancient genomes link early farmers from Atapuerca in Spain to modern-day Basques. *Proc Natl Acad Sci U S A*, 112: 11917-11922.

Juras A.

- 2014 Badania kopalnego DNA z cmentarzysk społeczności „wczesnobrązowych” na stanowisku Pidlisiwka 1 In: A. Koško, M. Potupczyk, S. Razumow (Eds), *Naddniestrzańskie kompleksy cmentarzysk kurhanowych społeczności z II i z pierwszej połowy II tysiąclecia przed Chr. w okolicach Jampola, obwód winnicki. Z badań nad północno-zachodnią rubieżą osadnictwa społeczności kręgu kultur „wczesnobrązowych” strefy pontyjskiej. Archaeologia Bimaris – Monografie* 6, 297-300. Poznań.

Juras A., Dabert M., Kushniarevich A., Malmström H., Raghavan M., Kosicki J.Z., Metspalu E., Willerslev E., Piontek J.

- 2014 Ancient DNA Reveals Matrilineal Continuity in Present-Day Poland over the Last Two Millennia. *PLoS ONE*: 9(10):e110839.

Kircher M.

- 2012 Analysis of high-throughput ancient DNA sequencing data. *Methods in Molecular Biology* 840: 197–228.

Kjellström A.

- 2004 Evaluations of Sex Assessment using Weighted Traits on Incomplete Skeletal Remains. *International Journal of Osteoarchaeology* 14: 360–373.

Koško A., Potupczyk M., Razumow S. (Eds)

- 2014 *Naddniestrzańskie kompleksy cmentarzysk kurhanowych społeczności z III i z pierwszej połowy II tysiąclecia przed Chr. w okolicach Jampola, obwód winnicki. Z badań nad północno-zachodnią rubieżą osadnictwa społeczności kręgu kultur „wczesnobrzązowych” strefy pontyjskiej. Badania z lat 1984-2014. Archaeologia Bimaris – Monografie 6. Poznań.*

Klochko V.I., Koško A., Potupchik M.V., Włodarczak P., Żurkiewicz D., Ivanova S.V.

- 2015 Tripolye (Gordinești group), Yamnaya and Catacomb culture cemeteries, Prydnistryanske, site 1, Yampil Region, Vinnitsa Oblast: an archaeometric and chronometric description and a taxonomic and topogenetic discussion. In: A. Koško (Ed.) *Podolia as a Cultural Contact Area in the 4th/3rd-2nd Millennium BC. Baltic-Pontic Studies* 20: 183-255.

Klochko V.I., Koško A., Razumov S.M., Włodarczak P., Żurkiewicz D.

- 2015a Eneolithic, Yamnaya, Catacomb and Babyno culture cemeteries, Pidlisivka, barrow 1, Yampil Region, Vinnitsa Oblast: archaeometry, chronometry and taxonomy. In: A. Koško (Ed.) *Podolia as a Cultural Contact Area in the 4th/3rd-2nd Millennium BC. Baltic-Pontic Studies* 20: 40-77.
- 2015b Eneolithic, Yamnaya and Noua culture cemeteries from the first half of the 3rd and the middle of the 2nd millennium BC, Porohy, site 3a, Yampil Region, Vinnitsa Oblast: archaeometric and chronometric description, ritual and taxonomic-topogenetic identification. In: A. Koško (Ed.) *Podolia as a Cultural Contact Area in the 4th/3rd-2nd Millennium BC. Baltic-Pontic Studies* 20: 78-141.
- 2015c Eneolithic, Babyno and Noua culture cemeteries, Klembivka, site 1, Yampil Region, Vinnitsa Oblast: archaeometry, taxonomy and topogenetics. In: A. Koško (Ed.) *Podolia as a Cultural Contact Area in the 4th/3rd-2nd Millennium BC. Baltic-Pontic Studies* 20: 142-182.

Lallo J.W., Armelagos G.J., Mensforth R.P.

- 1977 The role of diet, disease, and physiology in the origin of porotic hyperostosis. *Human Biology* 49(3): 471-83.

Lanphear K.M.

1990 Frequency and distribution of enamel hypoplasias in a historic skeletal sample. *American Journal of Physical Anthropology* 81(1): 35-43.

Li H., Durbin R.

2009 Fast and accurate short read alignment with Burrows–Wheeler transform. *Bioinformatics* 25(14): 1754-1760.

Li H., Handsaker B., Wysoker A., Fennell T., Ruan J., Homer N., Marth G., Abecasis G., Durbin R.

2009 The Sequence Alignment/Map format and SAM tools. *Bioinformatics* 25(16): 2078–2079.

Mathieson I., Lazaridis I., Rohland N., Mallick S., Patterson N., Roodenberg S.A., Harney E., Stewardson K., Fernandes D., Novak M., Sirak K., Gamba C., Jones E.R., Llamas B., Dryomov S., Pickrell J., Arsuaga J.L., de Castro J.M., Carbonell E., Gerritsen F., Khokhlov A., Kuznetsov P., Lozano M., Meller H., Mochalov O., Moiseyev V., Guerra M.A., Roodenberg J., Vergès J.M., Krause J., Cooper A., Alt K.W., Brown D., Anthony D., Lalueza-Fox C., Haak W., Pinhasi R., Reich D.

2015 Genome-wide patterns of selection in 230 ancient Eurasians. *Nature* 528(7583): 499-503.

Mensforth R.P., Lovejoy C.O., Lallo J.W., Armelagos G.J.

1978 Part Two: The role of constitutional factors, diet, and infectious disease in the etiology of porotic hyperostosis and periosteal reactions in prehistoric infants and children. *Medical Anthropology* 2(1): 1-59.

Meyer M, Kircher M.

2010 Illumina sequencing library preparation for highly multiplexed target capture and sequencing. *Cold Spring Harb Protoc* 6: t5448.

Molnar P., Ahlstrom T.P., Leden I.

2011 Osteoarthritis and Activity – An Analysis of the Relationship between Eburnation, Musculoskeletal Stress Markers (MSM) and Age in Two Neolithic Hunter-Gatherer Populations from Gotland, Sweden. *International Journal of Osteoarchaeology* 21: 283-291.

Pedersen P.O.

1938 Investigations into dental conditions of about 3000 ancient and modern Greenlanders. *Dental record* 24(7): 702-704.

Powel M.L.

1985 The Analysis of Dental Wear and Caries for Dietary Reconstruction. In:

- R.I. Gilbert, J.H. Mielke (Eds), *The Analysis of Prehistoric Diets*, 307-338. Orlando.
- Schaefer M., Black S., Scheuer L.
2009 *Juvenile Osteology: a Laboratory and Field Manual*. Oxford.
- Skoglund P., Storå J., Götherström A., Jakobsson M.
2013 Accurate sex identification of ancient human remains using DNA shotgun sequencing. *Journal of Archaeological Science* 40: 4477-4482.
- Steckel H., Larsen C.S., Sciulli P.W., Walker P.L.
2005 Data collection codebook. *The Global History of Health Project* <http://global.sbs.ohio-state.edu/docs/Codebook-12-12-05.pdf>.
- Svensson E.M., Anderung C., Baubliene J., Persson P., Malmström H., Smith C., Vretemark M., Daugnora L., Götherström A.
2007 Tracing genetic change over time using nuclear SNPs in ancient and modern cattle. *Animal Genetics* 38: 378-383.
- Šlaus M., Bedić Ž., Rajić Šikanjić P., Vodanović M., Domić - Kunić A.
2010 Dental health at the transition from the Late Antique to the early Medieval period on Croatia's eastern Adriatic coast. *International Journal of Osteoarchaeology* 21(5): 577-590.
- Trotter M., Gleser G.C.
1952 Estimation of stature from long bones of American Whites and Negroes. *American Journal of Physical Anthropology* 10(4): 463-514.
- Turner C.G.
1979 Dental anthropological indications of agriculture among the Jomon people of central Japan. X. Peopling of the Pacific. *American Journal of Physical Anthropology* 51(4): 619-635.
- Yang D.Y., Eng D., Wayne J.S., Dudar J.C., Saunders S.R.
1998 Technical note: Improved DNA extraction from ancient bones using silica based spin columns. *American Journal of Physical Anthropology* 105: 539-54.
- Weiss E., Jurmain R.
2007 Osteoarthritis Revised: A Contemporary Review of Etiology. *International Journal of Osteoarchaeology* 17: 437-450.
- Walker P.L., Erlandson J.M.
1986 Dental evidence for prehistoric dietary change on the northern Channel Islands, California. *American Antiquity* 51(2): 375-83.

Walker P.L., Bathurst R.R., Richman R., Gjerdrum T., Andrushko V.A.

2009 The Causes of Porotic Hyperostosis and Cribra orbitalia: A Reappraisal of the Iron-Deficiency-Anemia Reappraisal of the Iron-Deficiency-Anemia Hypothesis. *American Journal of Physical Anthropology* 139(2): 109-25.

White T.D., Folkens P.A.

2005 *The human bone manual*. Oxford.

LIST OF AUTHORS

Maciej Chyleński
Department of History
Institute of Prehistory, Faculty of History
Adam Mickiewicz University
Umultowska 89
61-614 Poznań, Poland
maciejchylenski@gmail.com

Tomasz Goslar
Faculty of Physics
Adam Mickiewicz University
Umultowska 85
61-614 Poznań, Poland
tomasz.goslar@radiocarbon.pl

Marta Gwizdała
Institute of Prehistory, Faculty of History
Adam Mickiewicz University
Umultowska 89
61-614 Poznań, Poland
marta-gwizdala@wp.pl

Svetlana V. Ivanova
Institute of Archaeology
National Academy of Science of Ukraine
Heroyiv Stalingrada 12
04210 Kyiv, Ukraine
svi1956@gmail.com

Mattias Jakobsson
Department of Organismal Biology
and SciLifeLab
Uppsala University
Norbyvägen 18C
SE-752 36 Uppsala, Sweden
mattias.jakobsson@ebc.uu.se

Anna Juras
Department of Human Evolutionary Biology
Institute of Anthropology, Faculty of Biology
Adam Mickiewicz University
Umultowska 89D
61-614 Poznań, Poland
ajuras.anthropology@gmail.com

Viktor I. Klochko
Department of Archaeology
National University of Kyiv-Mohyla Akademy
Skovorody 2
04665 Kyiv, Ukraine
vklochko@ukr.net

Aleksander Koško
Institute of Prehistory
Adam Mickiewicz University
Umultowska 89D
61-614 Poznań, Poland
antokol@amu.edu.pl

Liudmyla V. Litvinova
Department of Bioarchaeology
Institute of Archaeology
Ukrainian Academy of Science
Geroiv Stalingradaave. 12
04210 Kyiv, Ukraine
litvinovalv@ukr.net

Sylwia Łukasik
Department of Human Evolutionary Biology
Institute of Anthropology, Faculty of Biology
Adam Mickiewicz University in Poznań
Umultowska 89D
61-614 Poznań, Poland
lukasik@amu.edu.pl

Helena Malmström
Department of Organismal Biology
and SciLifeLab
Uppsala University
Norbyvägen 18C
SE-752 36 Uppsala, Sweden
helena.malmstrom@ebc.uu.se

Mykhailo V. Potupchik
Department of Culture and Arts
Khmelnyske St. 7
21036 Vinnitsa, Ukraine
m_potupchik@ukr.net

Serhiy M. Razumov
Taras Shevchenko University
October 25 128
3300 Tiraspol, Moldova
razum_22@rambler.ru

Marzena Szmyt
Institute of Eastern Studies
Adam Mickiewicz University
Umultowska 89D
61-614 Poznań, Poland
marzena@amu.edu.pl

Gennadiy N. Toshev
Zaporizhya National University
Zhukovskogo Street 66
69063 Zaporizhzhya, Ukraine
gent51@mail.ru

Piotr Włodarczak
Institute of Archaeology and Ethnology
of Polish Academy of Sciences
Centre for Mountains and Uplands
Archaeology in Kraków
Sławkowska 17
31-016 Kraków, Poland
wlodarczak.piotr@gmail.com

Danuta Żurkiewicz
Institute of Prehistory
Adam Mickiewicz University
Umultowska 89D
61-614 Poznań, Poland
danuta@amu.edu.pl

- Vol.1: *Weapons of the Tribes of the Northern Pontic Zone in the 16th–10th Centuries BC.*, by Viktor I. Klochko.
- Vol.2: *Nomadism and Pastoralism in the Circle of Baltic–Pontic Early Agrarian Cultures: 5000–1650 BC*, edited by Aleksander Koško.
- Vol.3: *Cemeteries of the Sofievka type: 2950–2750 BC*, edited by Aleksander Koško.
- Vol.4: *Eastern Exodus of the Globular Amphora People: 2950–2350 BC*, edited by Aleksander Koško.
- Vol.5: *Beyond Balkanization*, edited by Lucyna Domańska, Ken Jacobs.
- Vol.6: *The Trzciniec Area of the Early Bronze Age Civilization: 1950–1200 BC*, edited by Aleksander Koško.
- Vol.7: *The Foundations of Radiocarbon Chronology of Cultures Between the Vistula and Dnieper: 3150–1850 BC*, edited by Aleksander Koško.
- Vol.8: *Between West And East People of The Globular Amphora Culture in Eastern Europe: 2950-2350 BC*, by Marzena Szmyt.
- Vol.9: *The Western Border Area of the Tripolye Culture*, edited by Aleksander Koško.
- Vol.10: *Weaponry of Societes of the Northern Pontic Culture Circle: 5000–700 BC*, by Viktor I. Klochko.
- Vol.11: *Fluted Maces in the System of Long-Distance Exchange Trails of the Bronze Age: 2350–800 BC*, edited by Aleksander Koško.
- Vol.12: *The Foundations of Radiocarbon Chronology of Cultures Between the Vistula and Dnieper: 4000–1000 BC*, edited by Aleksander Koško and Viktor I. Klochko.
- Vol.13: *Funeral Rites of the Catacomb Community: 2800–1900 BC Ritual, Thanatology and Geographical Origins*, by Katarzyna Ślusarska.
- Vol.14: *Routes between the Seas: Baltic-Bug-Boh-Pont from the 3rd to the Middle of the 1st Millennium BC*, edited by Aleksander Koško and Viktor I. Klochko.
- Vol.15: *‘Cord’ Ornaments on Pottery in the Vistula and Dnieper Interfluvial Region: 5th – 4th Mill. BC*, edited by Aleksander Koško and Marzena Szmyt.
- Vol.16: *Flint Artefacts of Northern Pontic Population of the Early and Middle Bronze Age: 3200–1600 BC*, by Serhiy M. Razumov
- Vol.17: *Wood Tar in the Dnieper and Elbe Communities: VI – II Millenium BC*, by Sławomir Pietrzak
- Vol.18: *The Ingul-Donets Early Bronze Civilization as Springboard for Transmission of Pontic Cultural Patterns to the Baltic Drainage Basin 3200–1750 BC*, edited by Aleksander Koško and Viktor I. Klochko.
- Vol.19: *Reception Zones of ‘Early Bronze Age’ Pontic Culture Traditions: Baltic Basin – Baltic and Black Sea Drainage Borderlands, 4/3 Mill. to First Half 2 Mil. BC*, edited by Aleksander Koško and Viktor I. Klochko.

Orders regarding *Baltic-Pontic Studies* should be adressed directly to the Editorial Office (*BPS*, Institute of Prehistory, Umultowska 89D, 61-614 Poznań, Poland).
 E-mail: iplib@amu.edu.pl; antokol@amu.edu.pl
 Moreover, we are pleased to inform that *BPS* volumes currently out of print (1-19) are available online at the Adam Mickiewicz University Repository (AMUR): repozytorium.amu.edu.pl

This publication constitutes the fruits of the National Programme for the Development of the Humanities (grant no. 0108/NPH3/H12/82/2014).